Inside-out Central Venous Access

John C Gurley, MD
University of Kentucky

May 9, 2012

Presenter Disclosure Information

John C Gurley, MD
Inside-out Central Venous Access

FINANCIAL DISCLOSURE:
Grants/Research Support: *None*
Speakers Bureau: *None*
Development Interests: Therix Medical, Bluegrass Vascular Technologies

UNLABELED/UNAPPROVED USES DISCLOSURE:
This presentation describes hardware that has been modified and/or utilized in a manner that is not consistent with labeled instructions for use. Inside-out Central Venous Access (IOCVA) is an unproven procedure with unknown risks.

The ideal configuration for CIEDs

- Transvenous leads + pre-pectoral pulse generator
  - Comfort
  - Stability
  - Defib efficacy
  - Safety
- Nothing else comes close

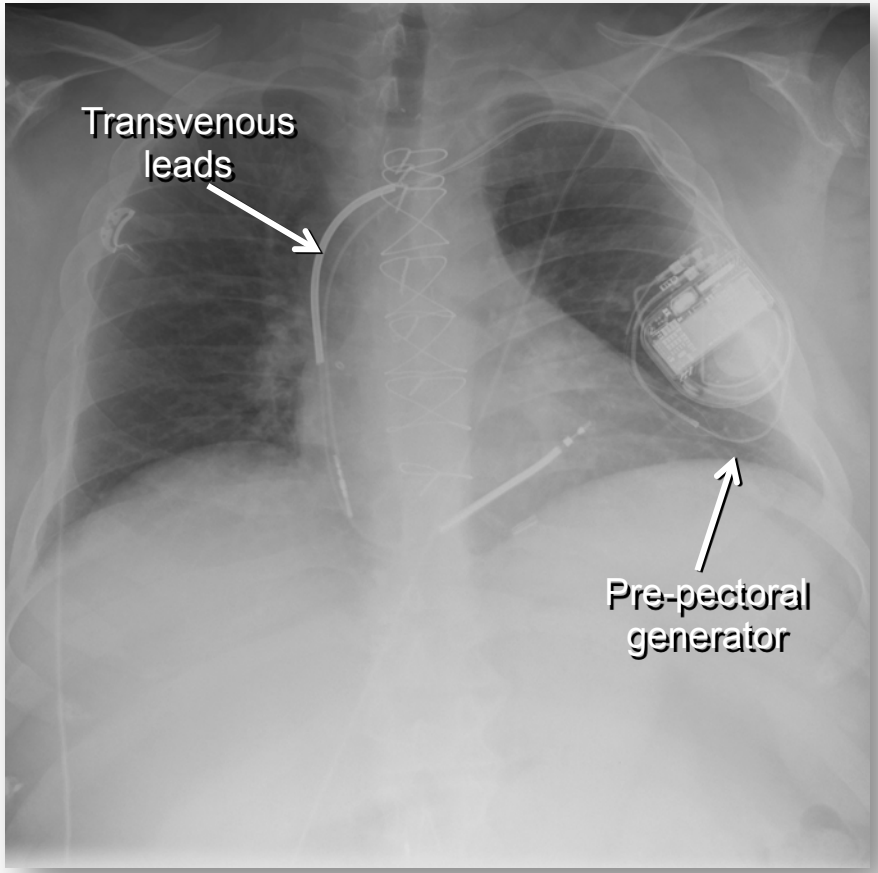

The most common cause of implant failure

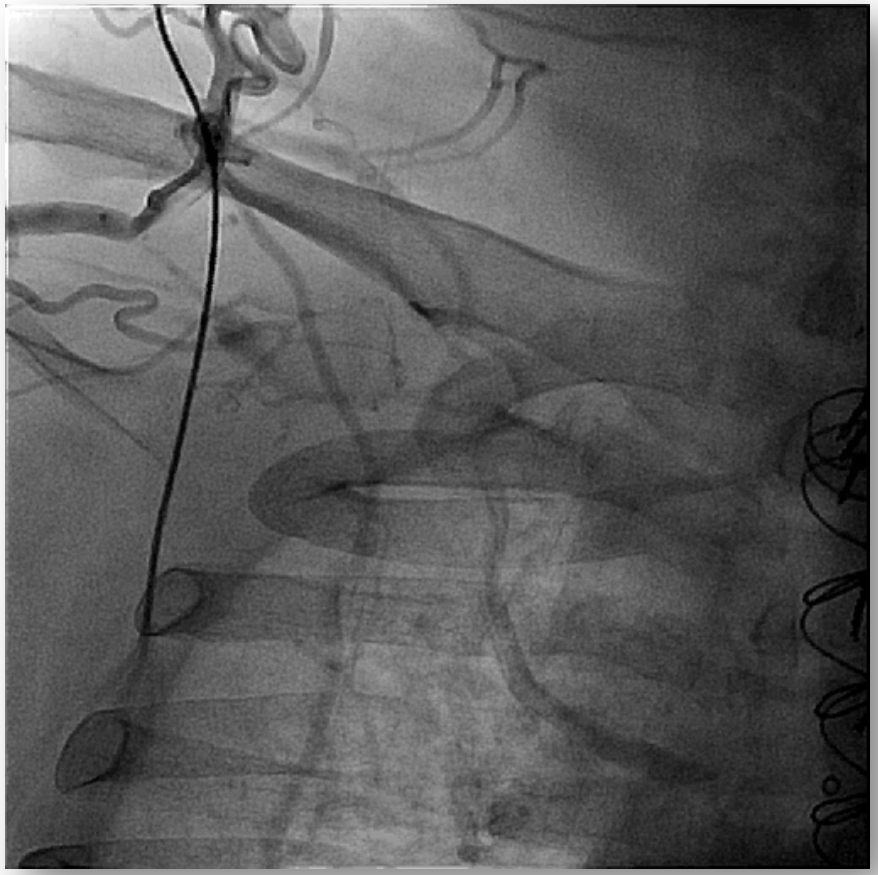

Most occlusions are iatrogenic

- Problem will increase as the population ages
- Procedures obstruct central veins
  - Hemodialysis access
  - Central lines
  - CIEDs
- Exploit the remaining veins until all are gone
  - Access crisis

Some occlusions can be managed with conventional methods

- Interventional recanalization and venoplasty
- Lead extraction
  - Retains lumen for new leads
  - Significant risks[1]

1. Hauser RG, et. al. Europace. 2010;12(3):395-401.

Trans-iliac approach: reasons to avoid

- Frequent late complications
  - 4 studies, 150 patients since 1989 [1-3]
  - Poor lead stability
  - Atrial lead dislodgment in 17%
  - Pocket erosion, lead fracture, discomfort
- DVT hazard
  - Magnitude of DVT/PE risks are unknown
  - DVT 25% with temporary femoral wires[4,5]
- Poor shock vectors
  - Abdominal generator, no SVC coil
  - 1/3rd require subcutaneous coils [6]
  - 13% late complications

Gopinathannair. Journal of Innovations in Cardiac Rhythm Management 2010;1:105–106

1. Ellestad. Pacing Clin Electrophysiol 1989;12:1030–1033.
2. Mathur. Europace 2001;3:56 –59.
3. Erdogan. Am J Cardiol 1999;84:474-475, A9-A10.
4. Cohen. Circulation 1974;49:1018 –1019.
5. Pandian. Am Heart J. 1980 Dec;100(6 Pt. 1):847-51.
6. Ching. Heart Rhythm 2009;6:978– 983.

Surgical lead placement: reasons to avoid

- Morbidity of VATS, minimally invasive approaches [1-2]
  - Mean hospital stay 4.6 days
  - Surgical mortality 4.8%
  - Hypotension and pulmonary edema in 27%
  - Total complications in 70% (bleeding, pleural effusions, perforation, pneumonia, AF, etc.)
- Minimally invasive surgical versus transvenous [3]
  - More acute renal failure (26.2% vs 4.9%, P<.001)
  - More infections (11.9% vs 2.4%, P <.03)
- Sensing/pacing performance of epicardial leads
- Defib systems may require additional coils/patches
- Epicardial leads not easily replaced or revised

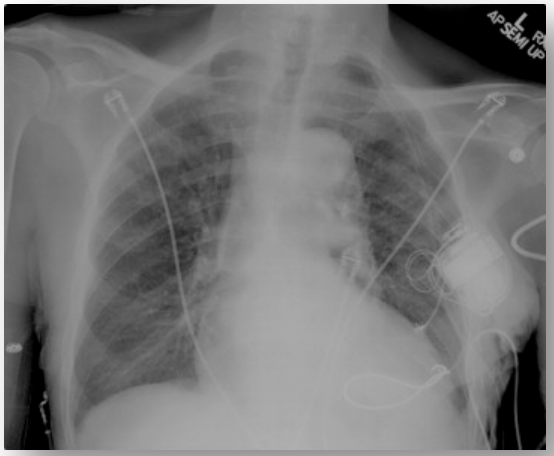

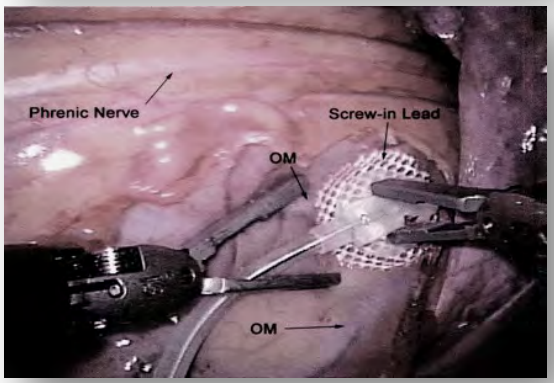

1. Molina JE et. al. J Interv Card Electrophysiol 2004;11:149-154.
2. Jaroszewski DE et. al. Ann Thorac Surg 2009;88:112-116.
3. Ailawadi G,et al. Heart Rhythm 2010;7:619-625.
4. Image source: DeRose JJ et. al. J Am Coll Cardiol. 2003;41(8):1414-9.

Central venous obstruction increases surgical bleeding

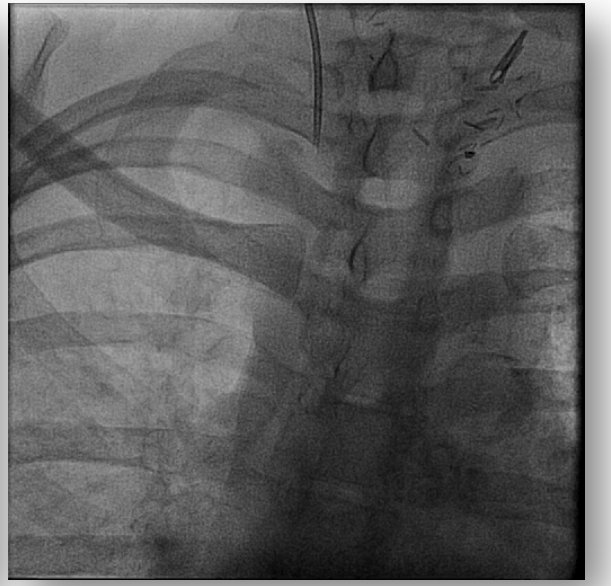

Image size: 512 x 512
View size: 647 x 647
WL: 107 WW: 187
HICOR062322011090117214 6 (-, -)
-- unnamed
20110901172146
1
200
107
14
Zoom: 126% Angle: 0
Im: 1/102
JPEGBaseline
9/1/11 5:45:23 PM
Made In OsiriX

Surgery should be the last resort for lead placement, especially in patients with central vein occlusions.

Inside-out central venous access

- Percutaneous procedure
- Local anesthesia & conscious sedation
- Conventional transvenous leads
- Pre-pectoral pulse generators
- Supports CRT

Anatomical basis for Inside-out access

Interventional Device Implantation

Techniques for Overcoming Difficult Anatomy

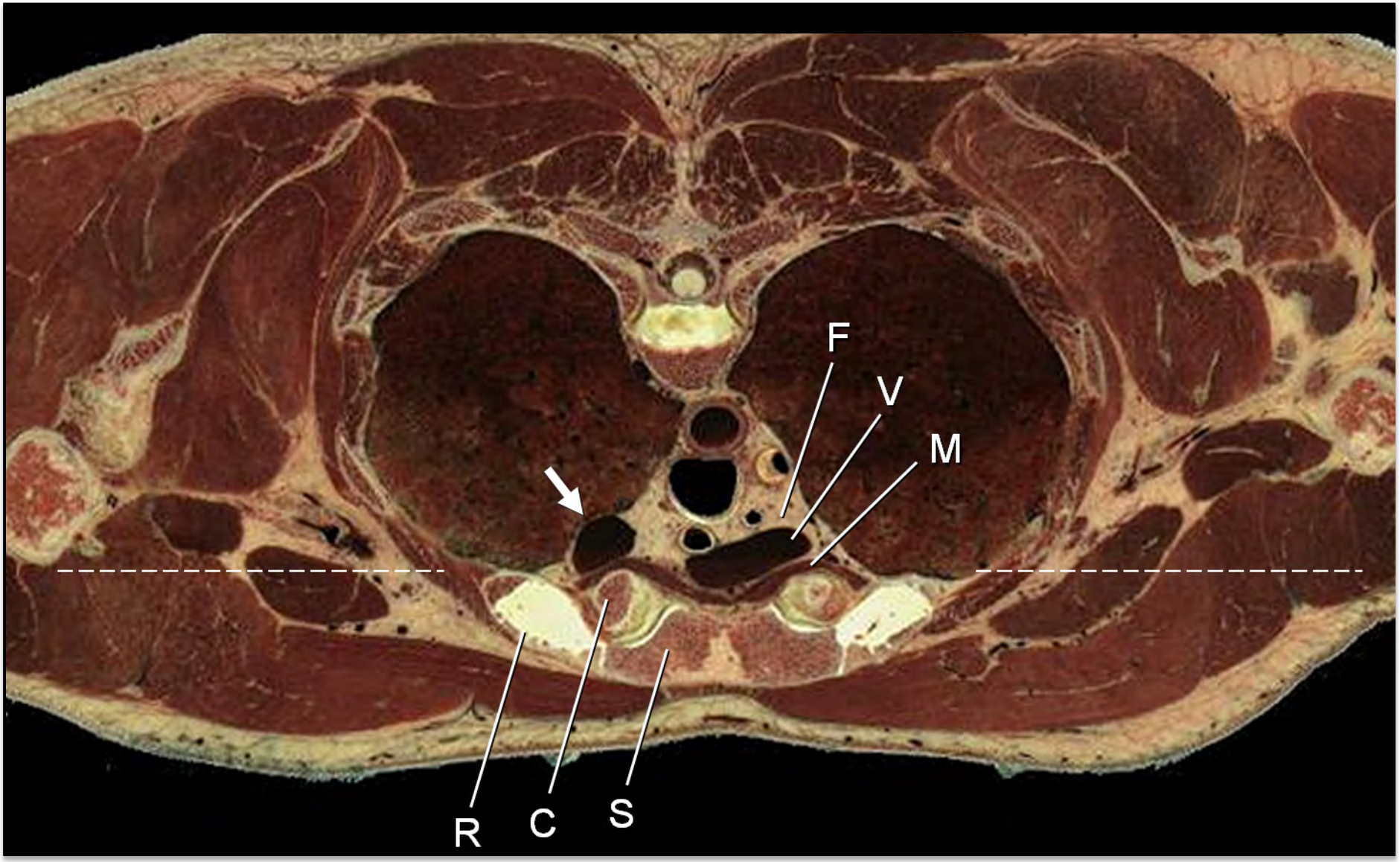

Interventional Device Implantation

Techniques for Overcoming Difficult Anatomy

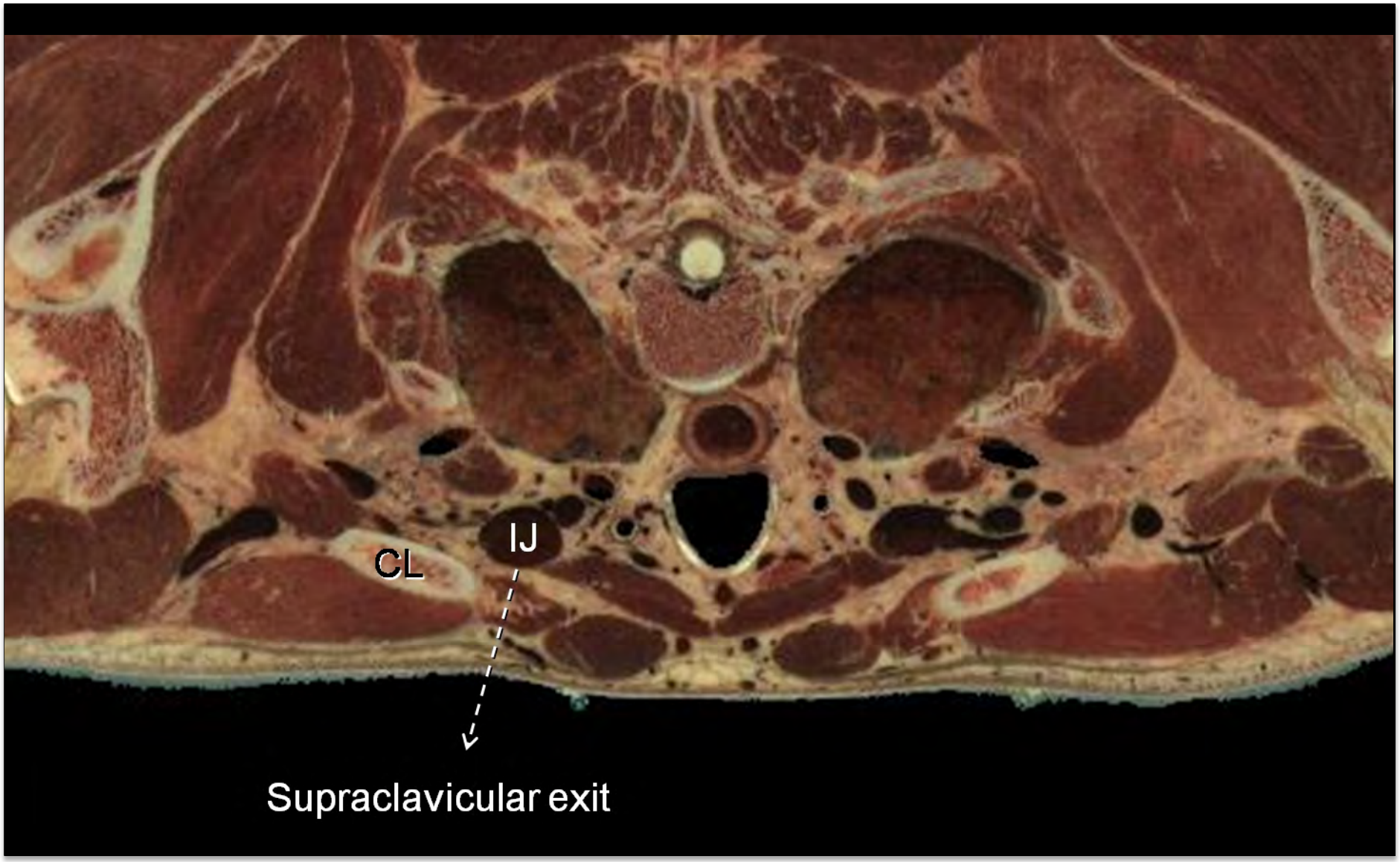

Interventional Device Implantation

Techniques for Overcoming Difficult Anatomy

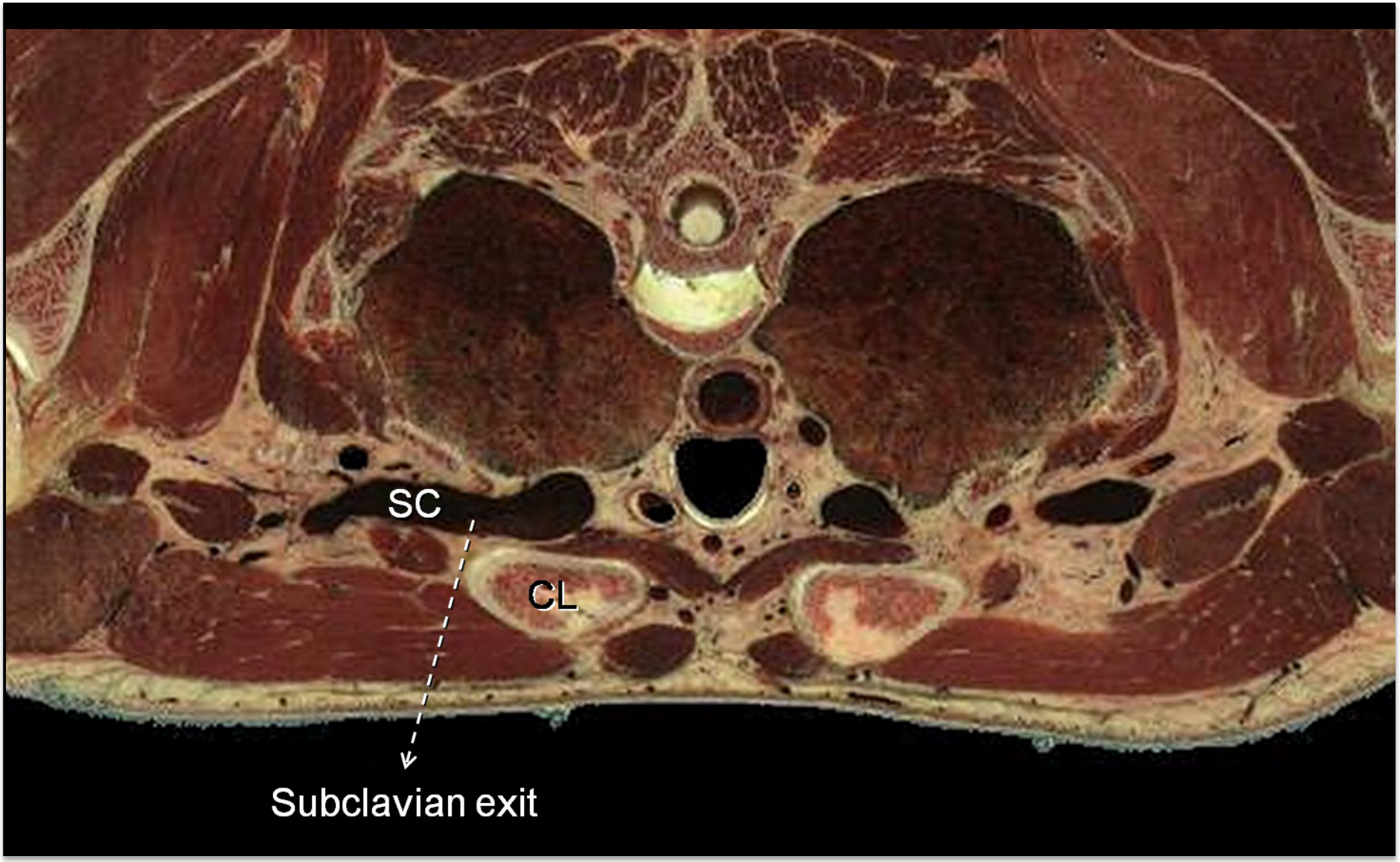

Case study #1: IOCVA for placement of a subcutaneous port

- A 45 year old man with short bowel syndrome
- Long-term dependency on TPN
- Occlusions managed w/ stiff guidewires and balloons
- Now unable to cross despite aggressive attempts
- Failed attempt at femoral port
- No source of nutrition

Complex central vein occlusions

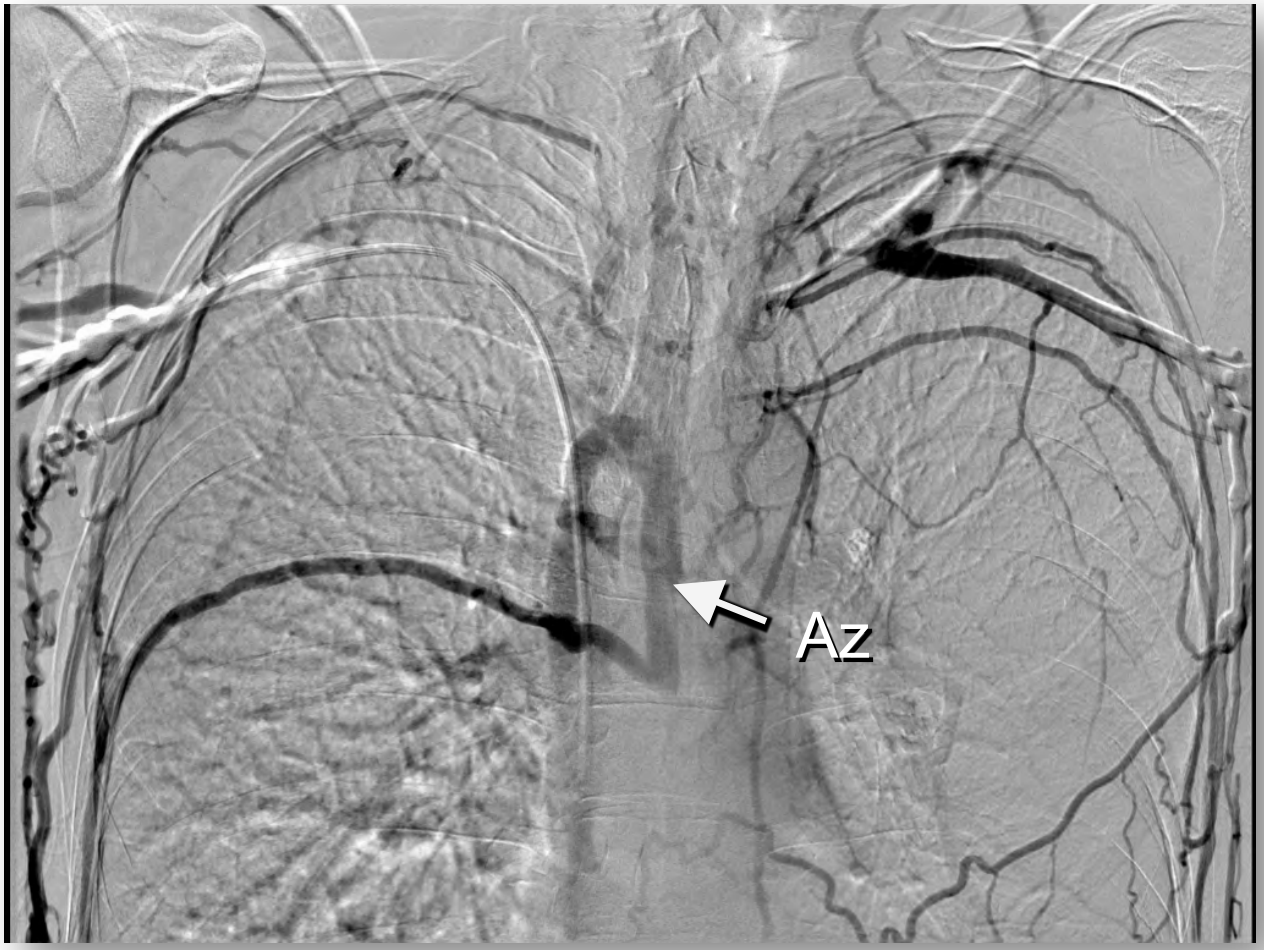

Interventional Device Implantation

Techniques for Overcoming Difficult Anatomy

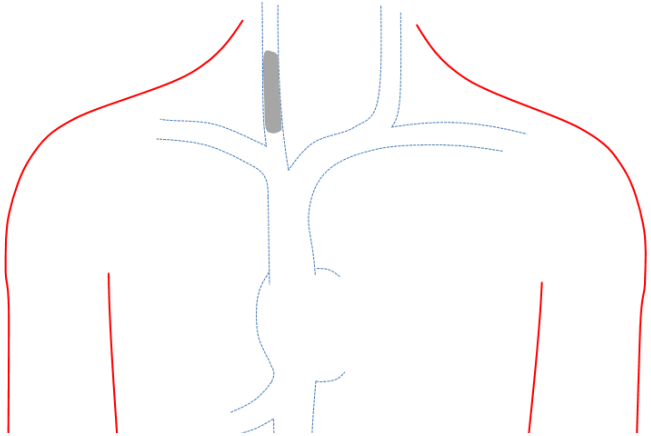

Type 1. IJ and/or SC occlusion

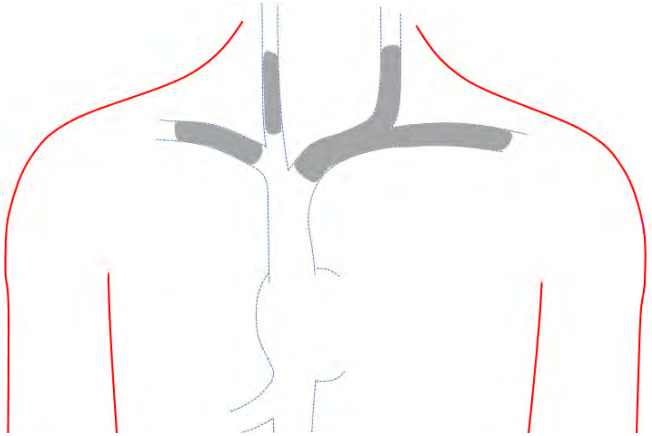

Type 2. Brachiocephalic w/ patent SVC

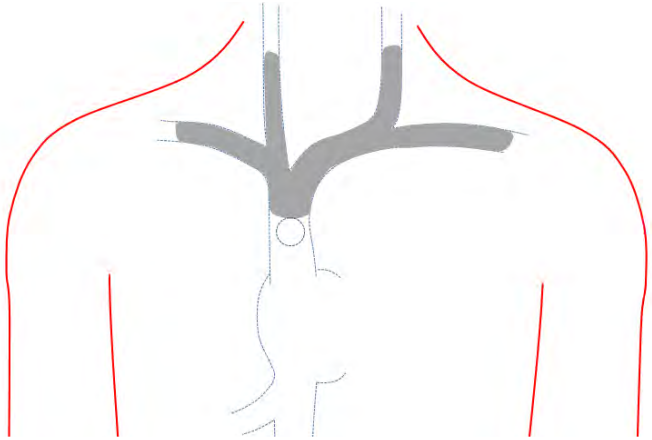

✓ **Type 3.** SVC above azygos

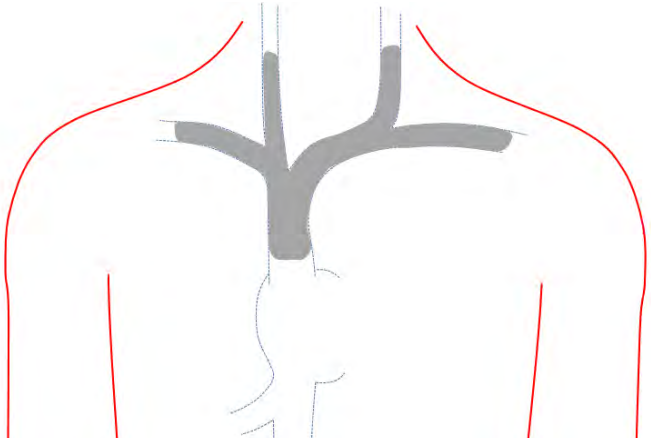

Type 4. SVC below azygos

Identify the SVC stump (RAO 30°)

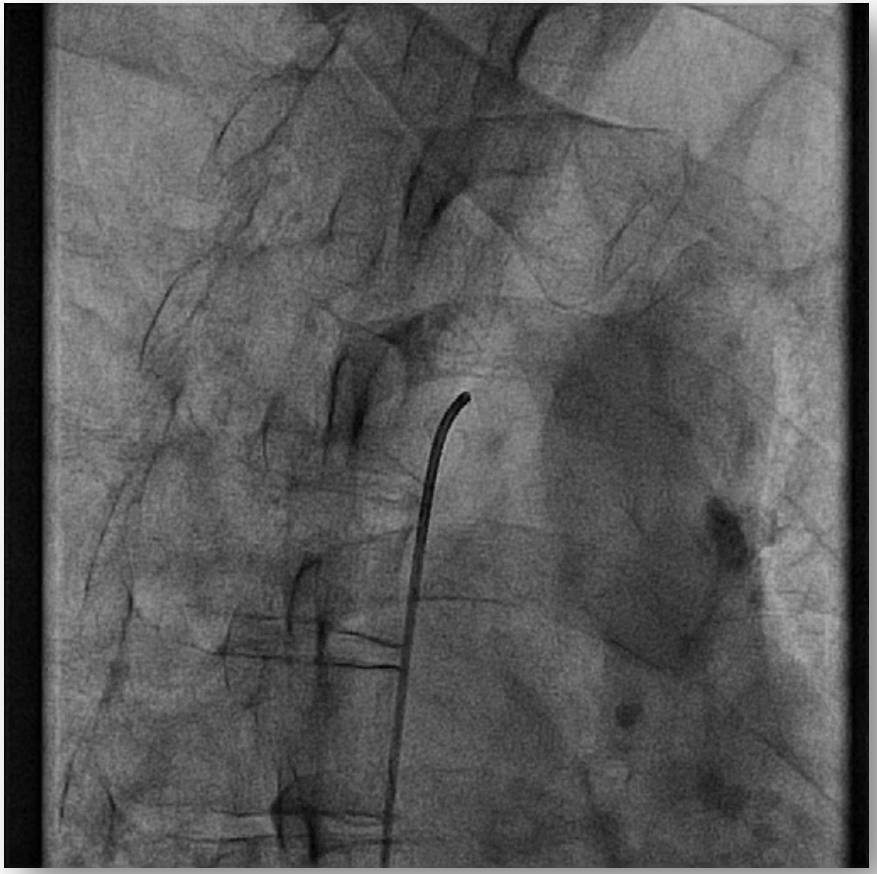

Interventional Device Implantation

Techniques for Overcoming Difficult Anatomy

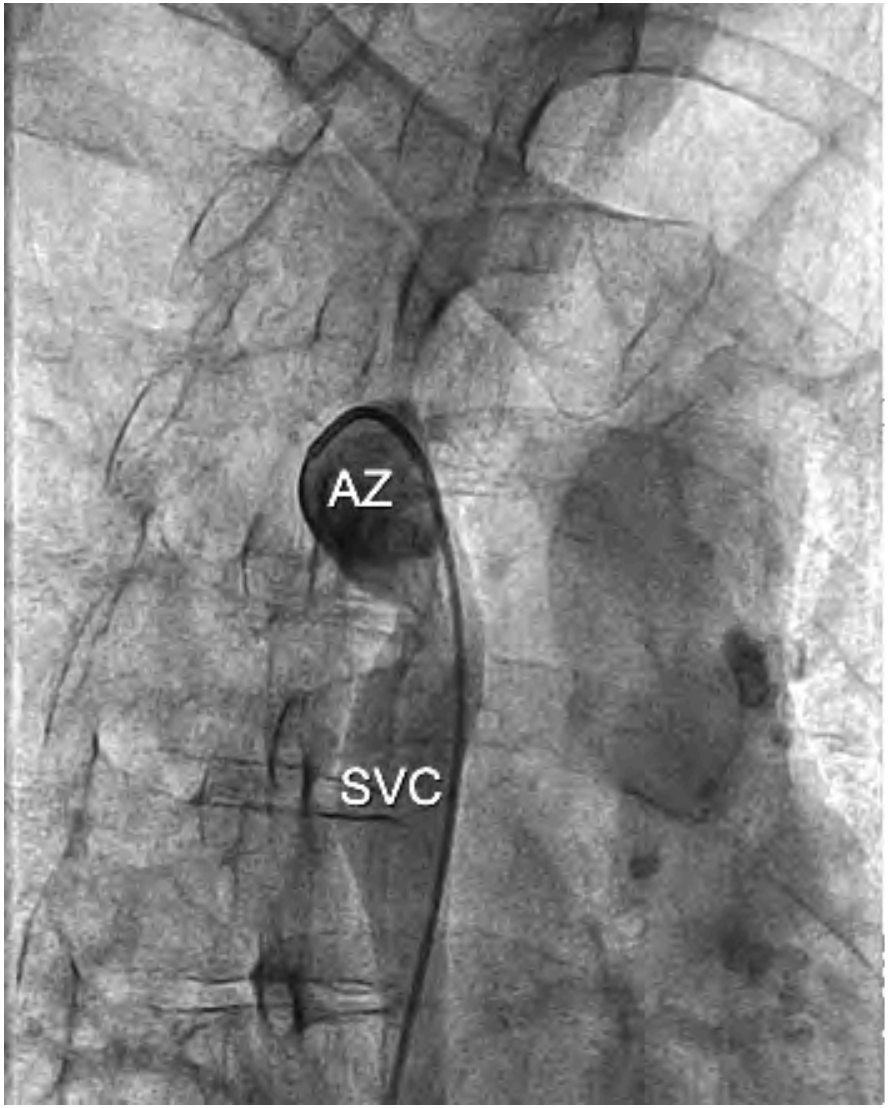

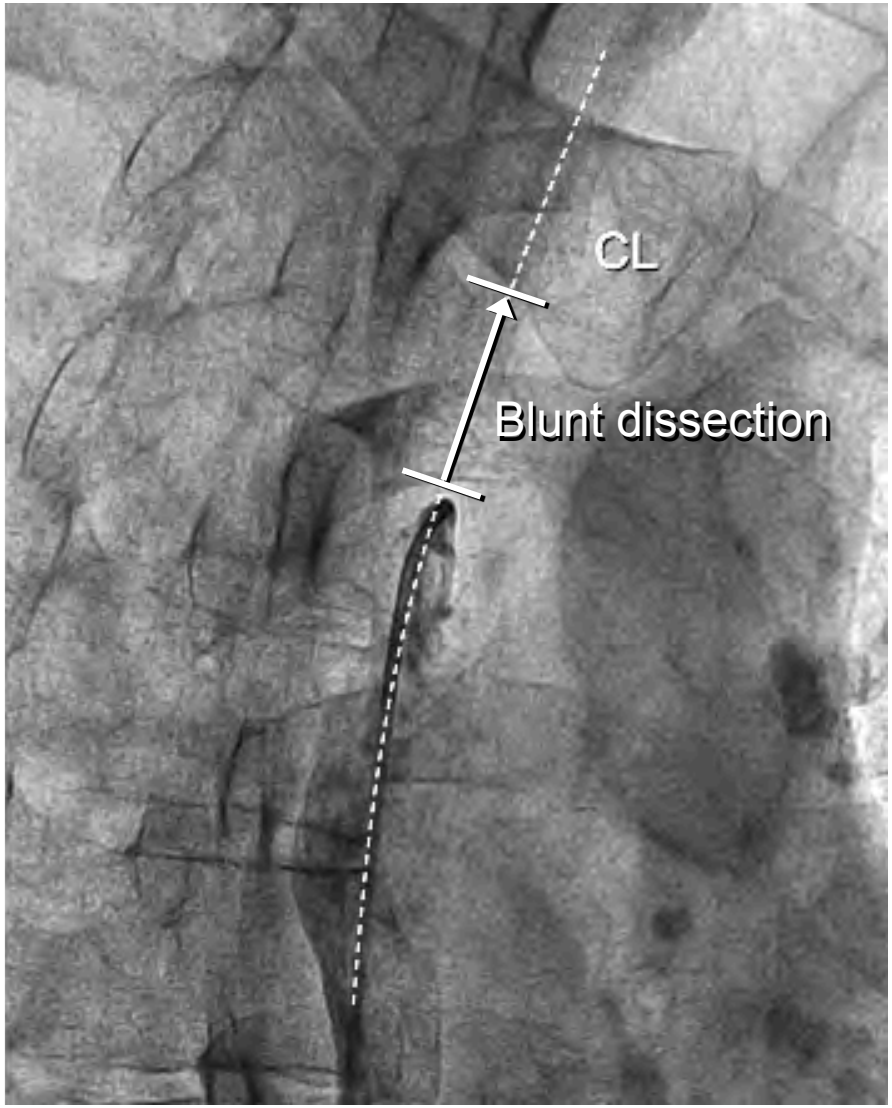

Position at posterior surface of clavicle

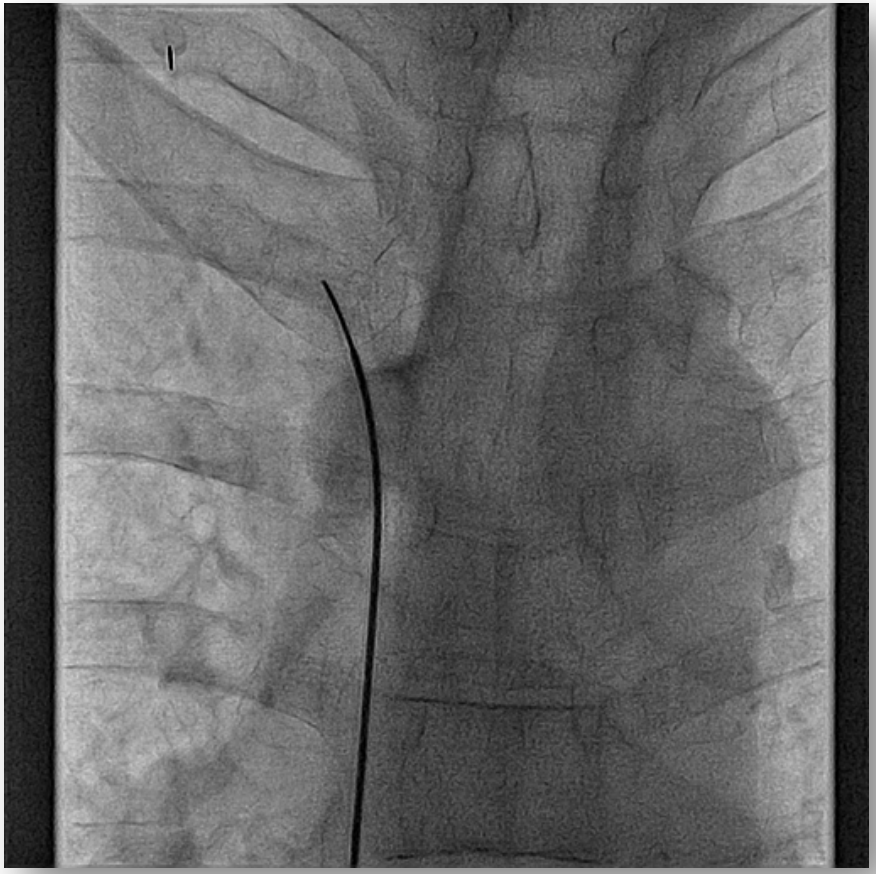

Prepare sharpened .018” wire

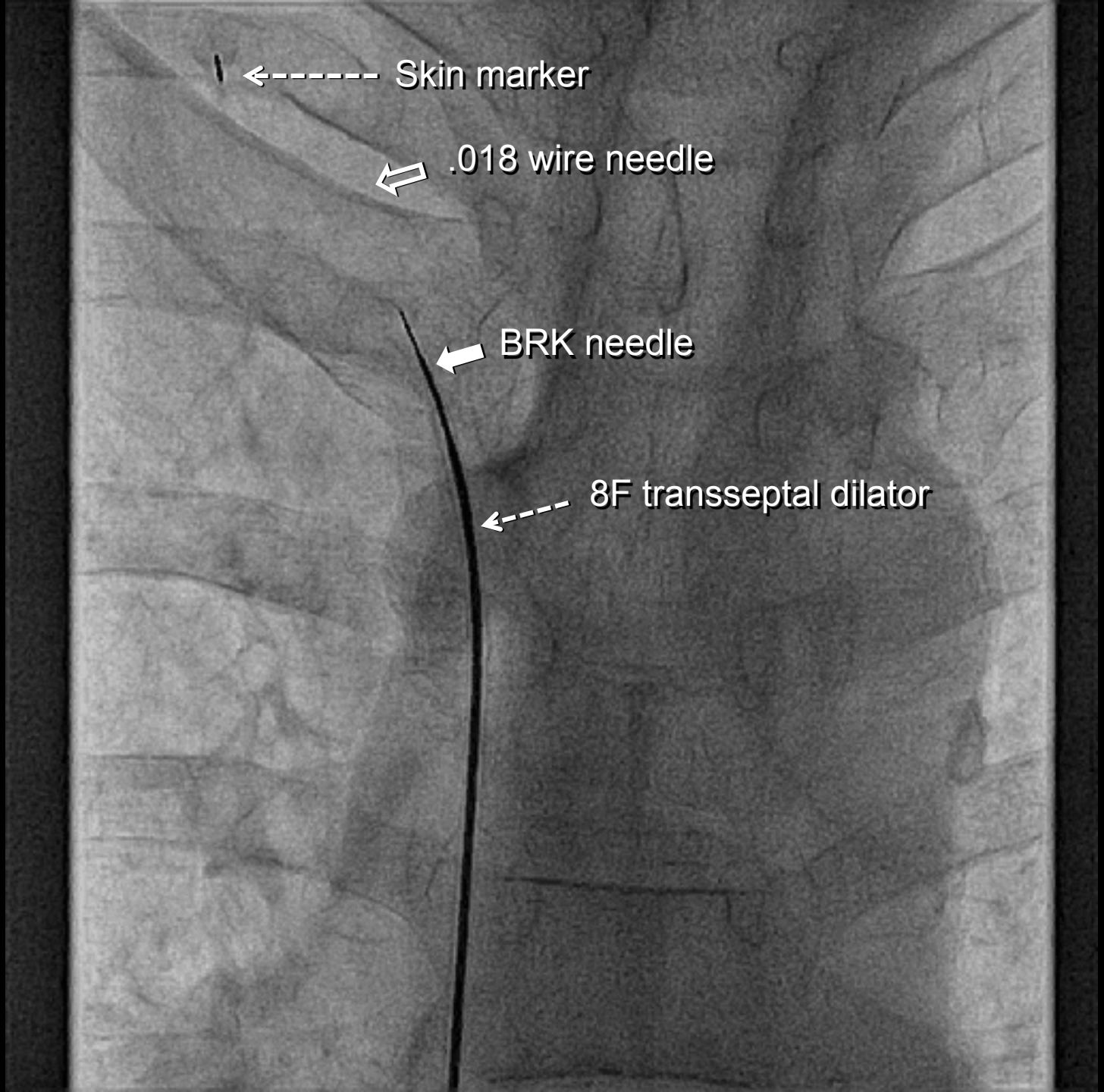
Skin marker
.018 wire needle
BRK needle
8F transseptal dilator

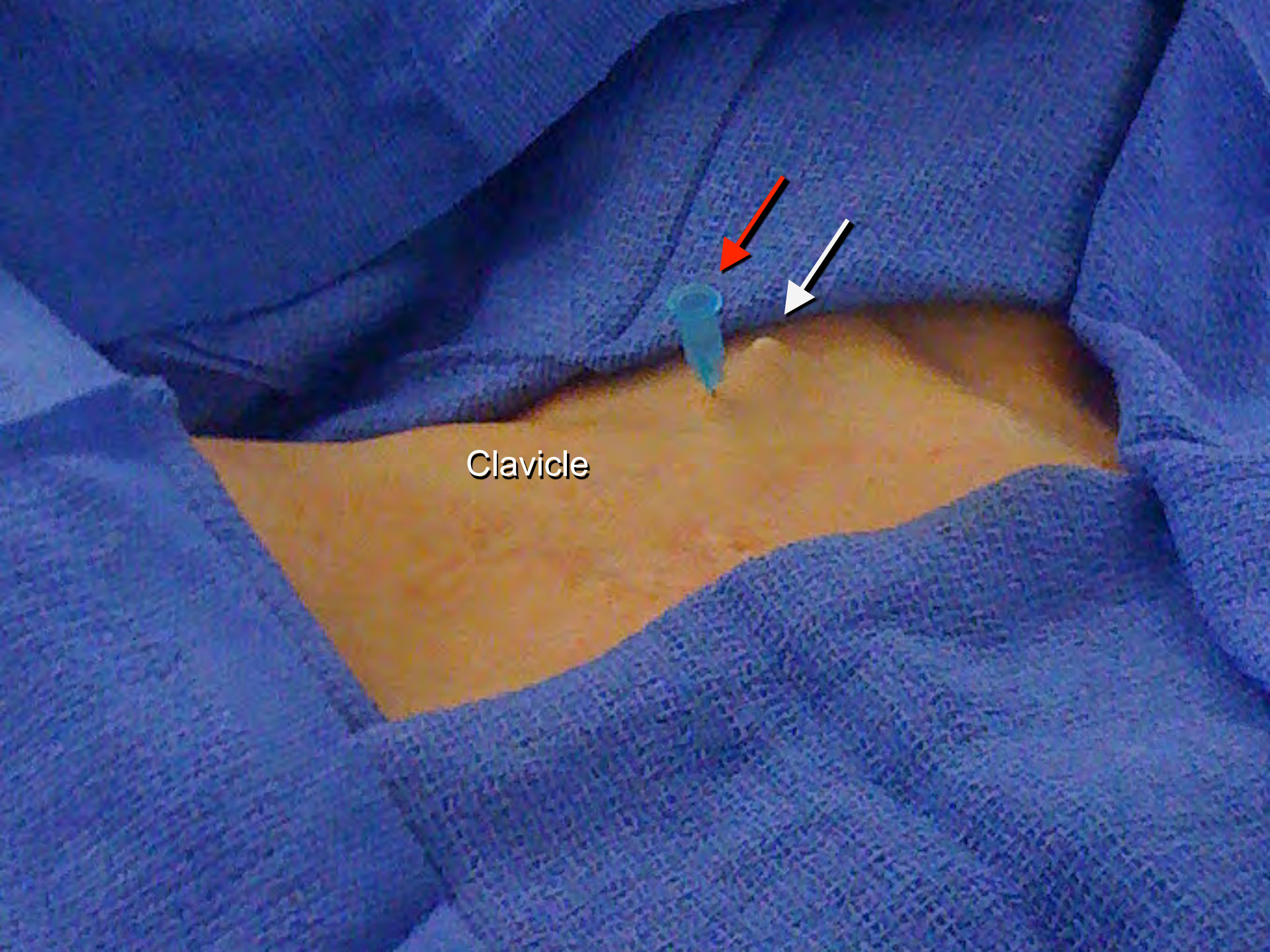
Clavicle

Femoral view

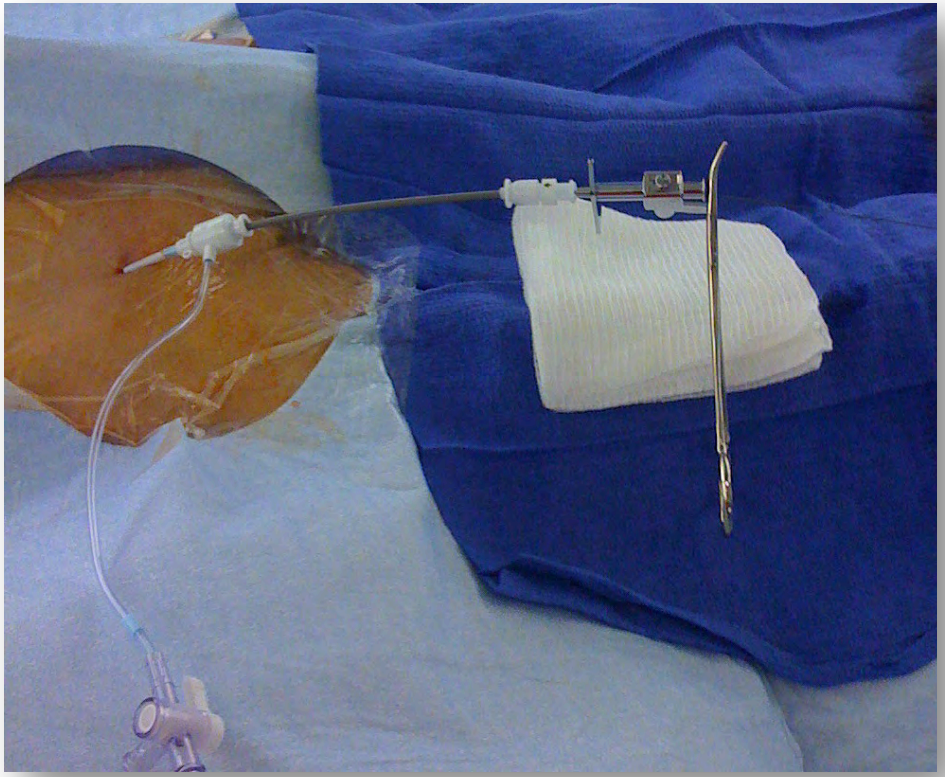

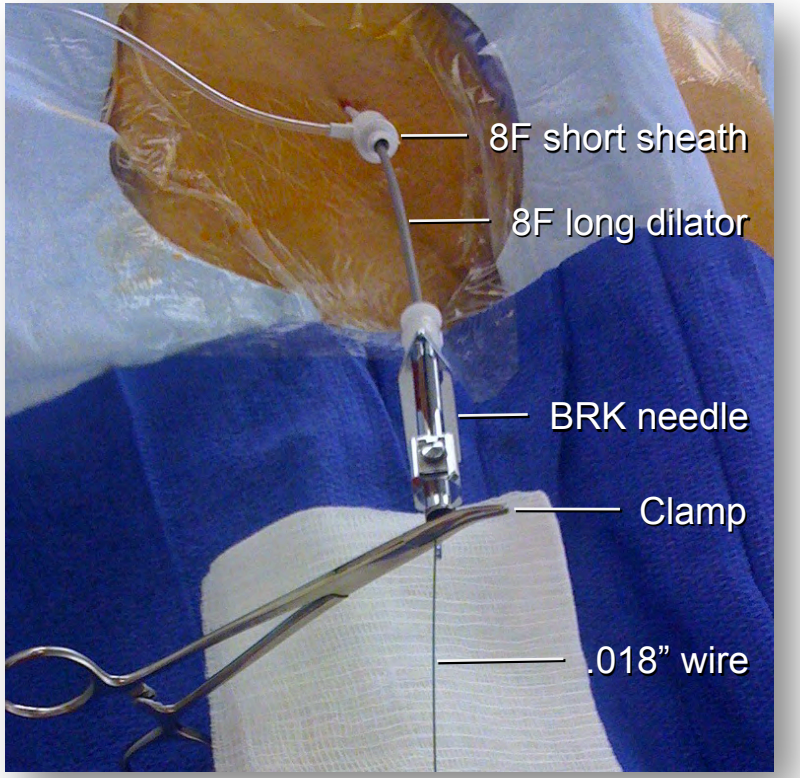

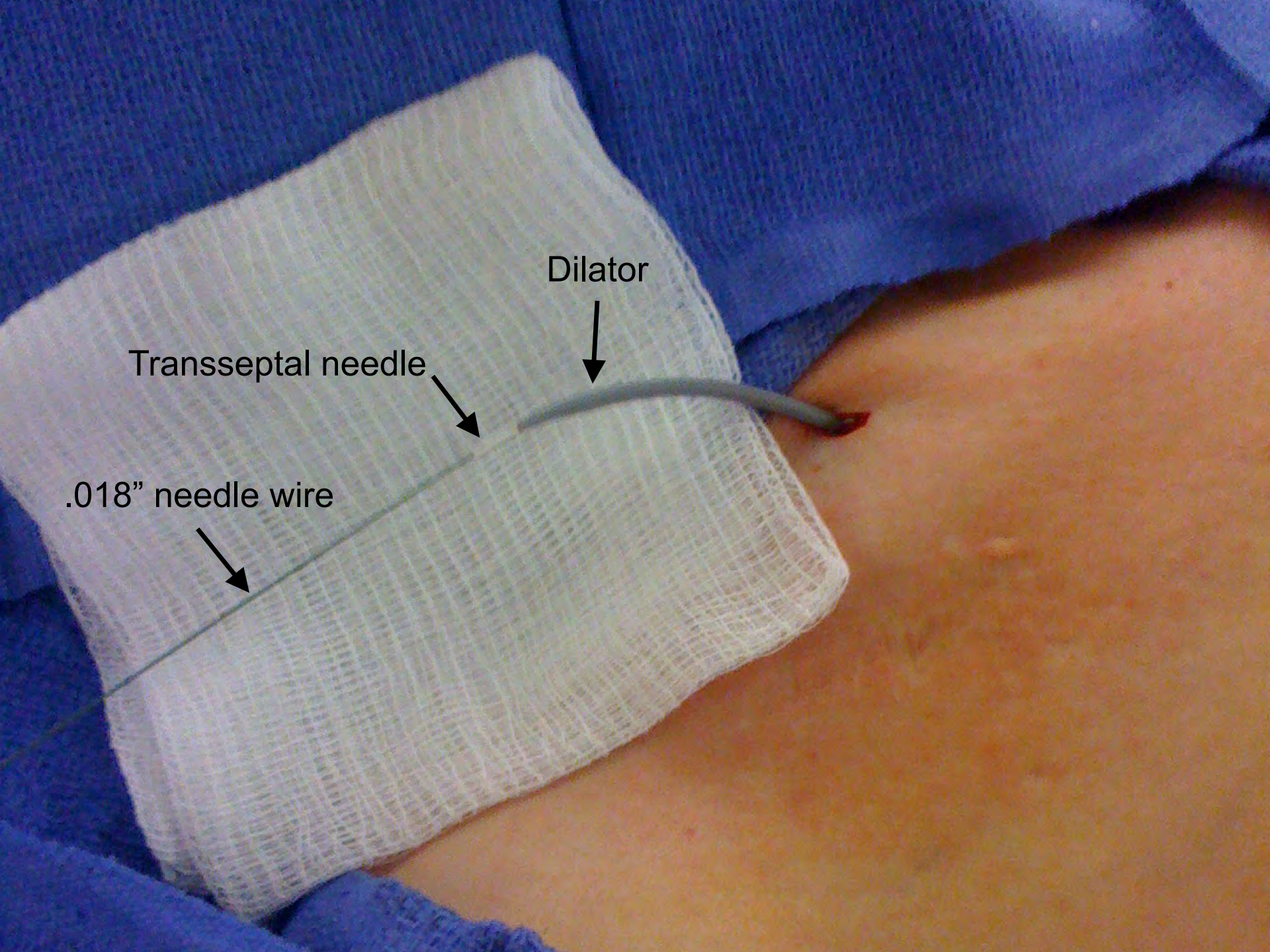
Dilator
Transseptal needle
.018” needle wire

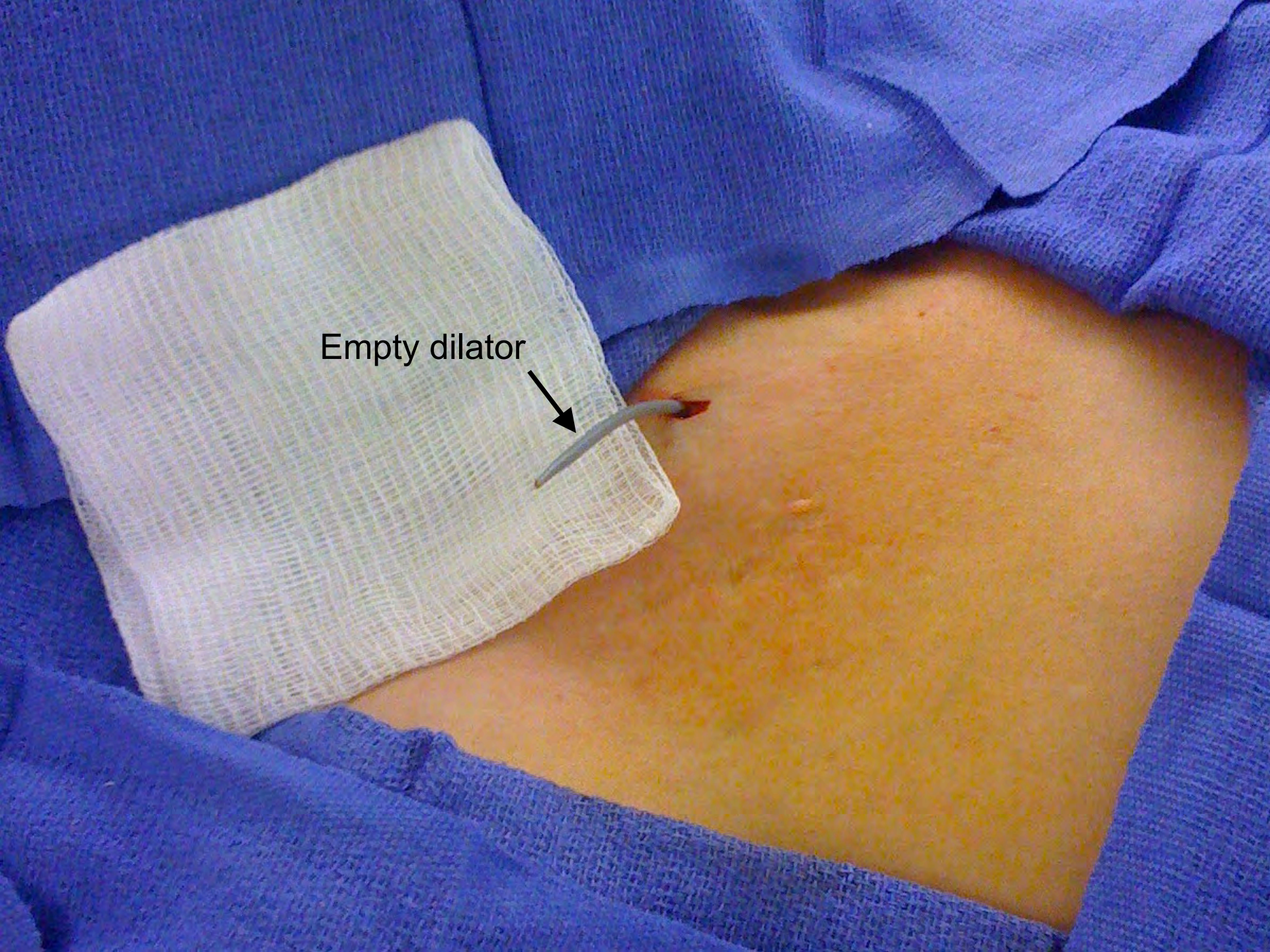
Empty dilator

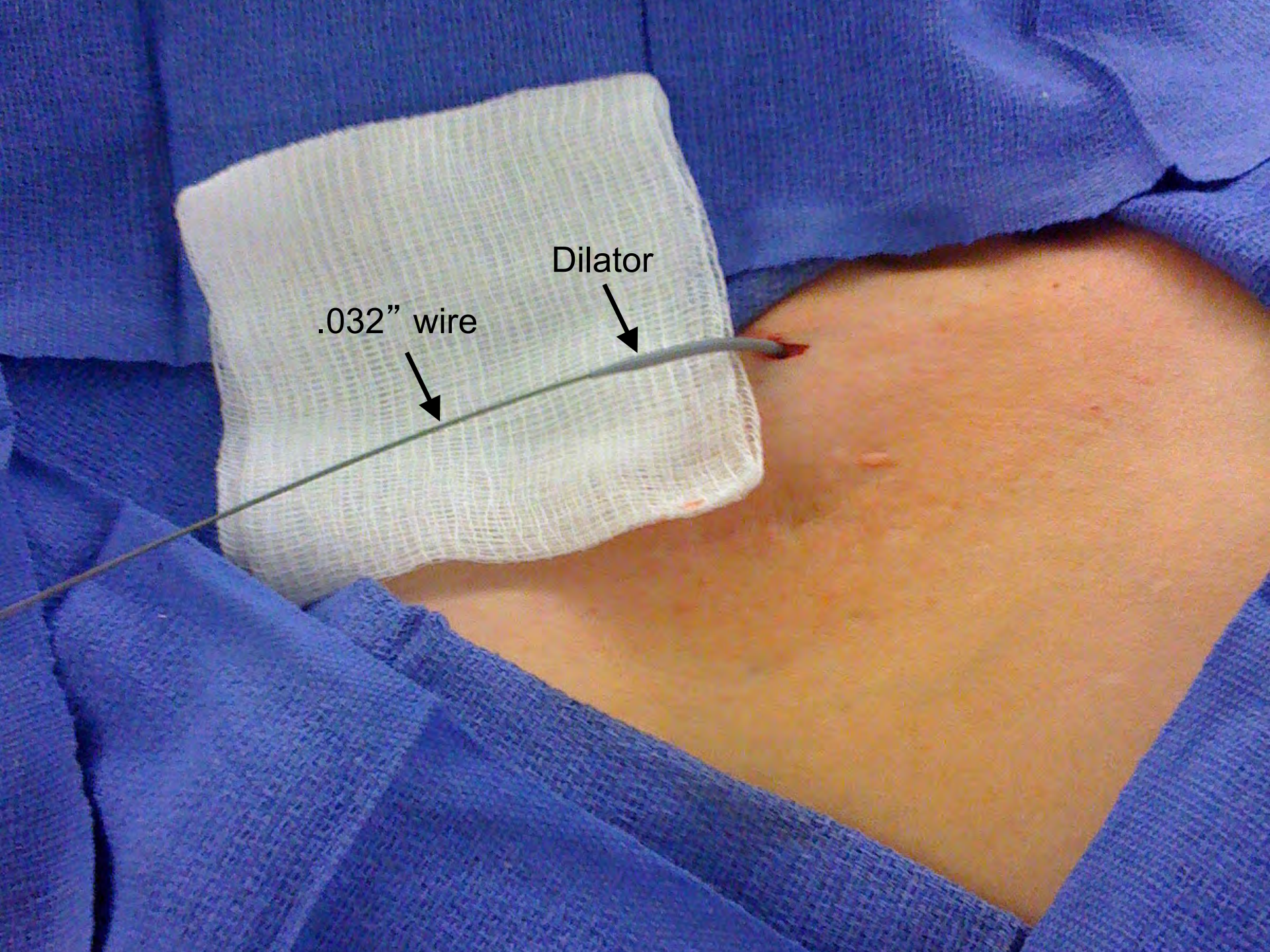
Dilator
.032” wire

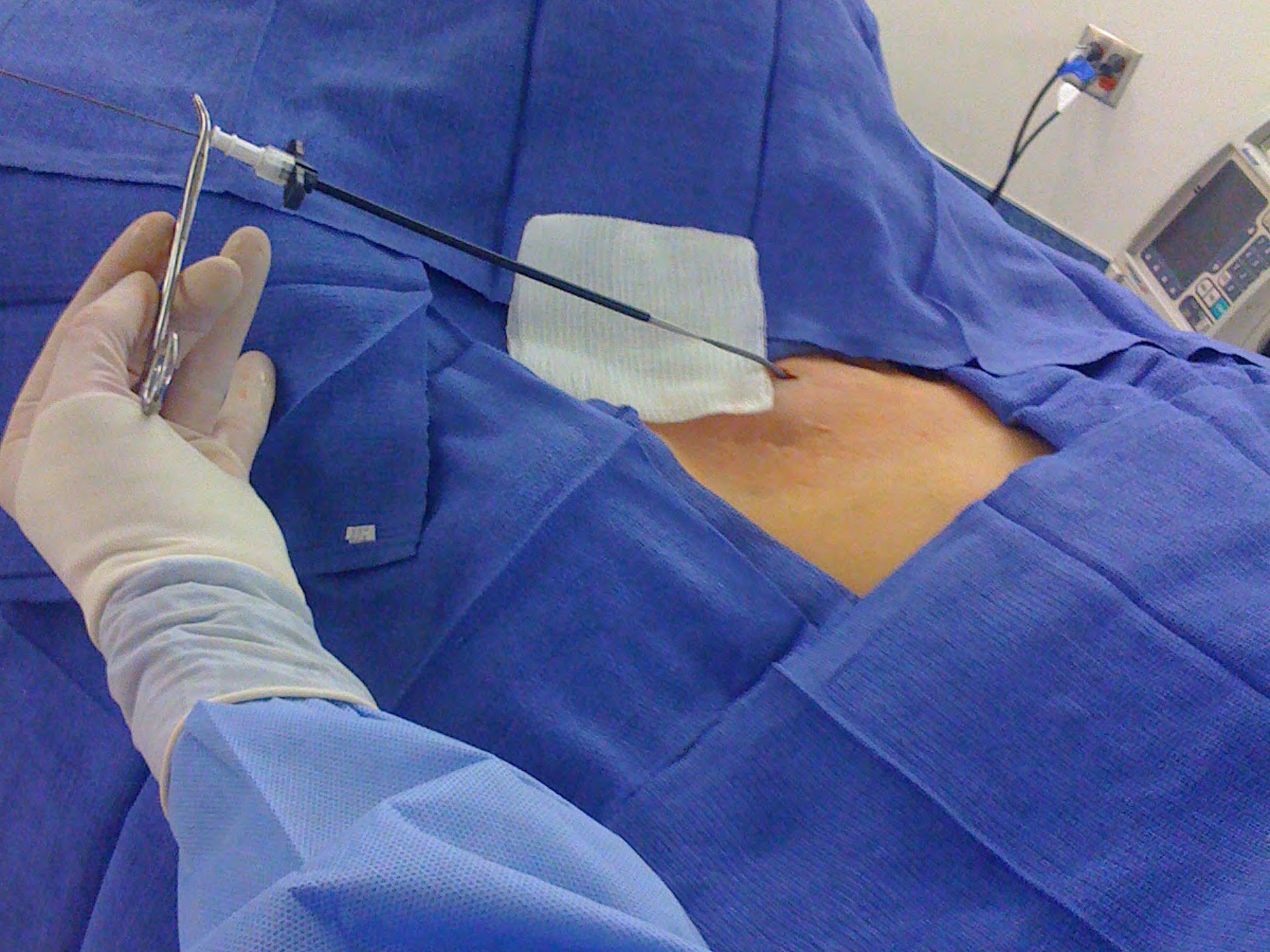

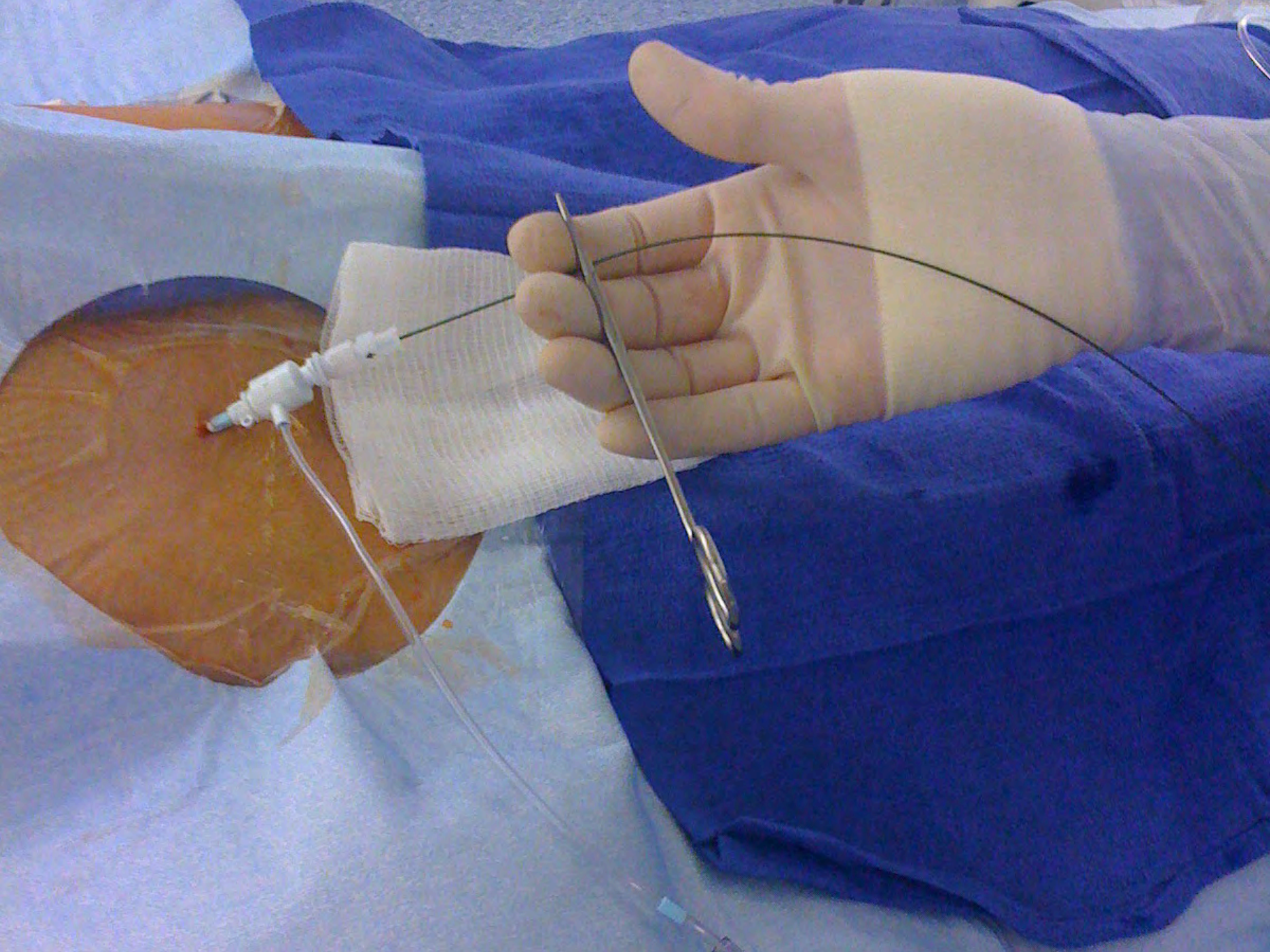

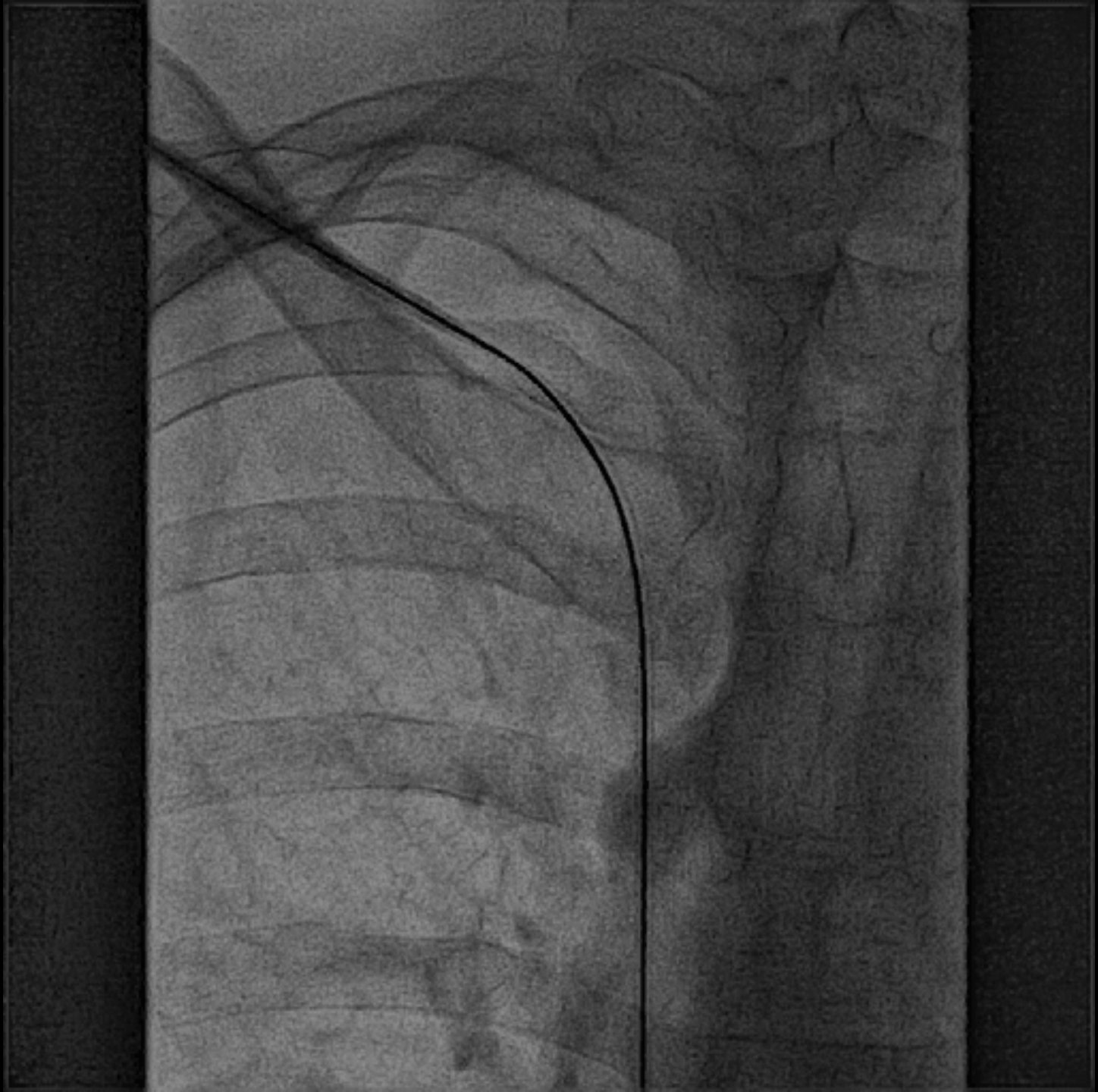

Completion fluoroscopy

Case study #2: Right supraclavicular approach IOCVA for CRT-D

- 61 year old woman with nonischemic CM, NYHA class III, LVEF <30%, wide LBBB
- Past history of fibrosing mediastinitis
  - SVC occlusion x 15 years
  - Extensive collateral veins
- Failed interventional access x 2
- Failed thoracotomy
  - Aborted due to major bleeding
  - Unable to place LV or defibrillation leads

Chronic total occlusion at SVC-RA junction

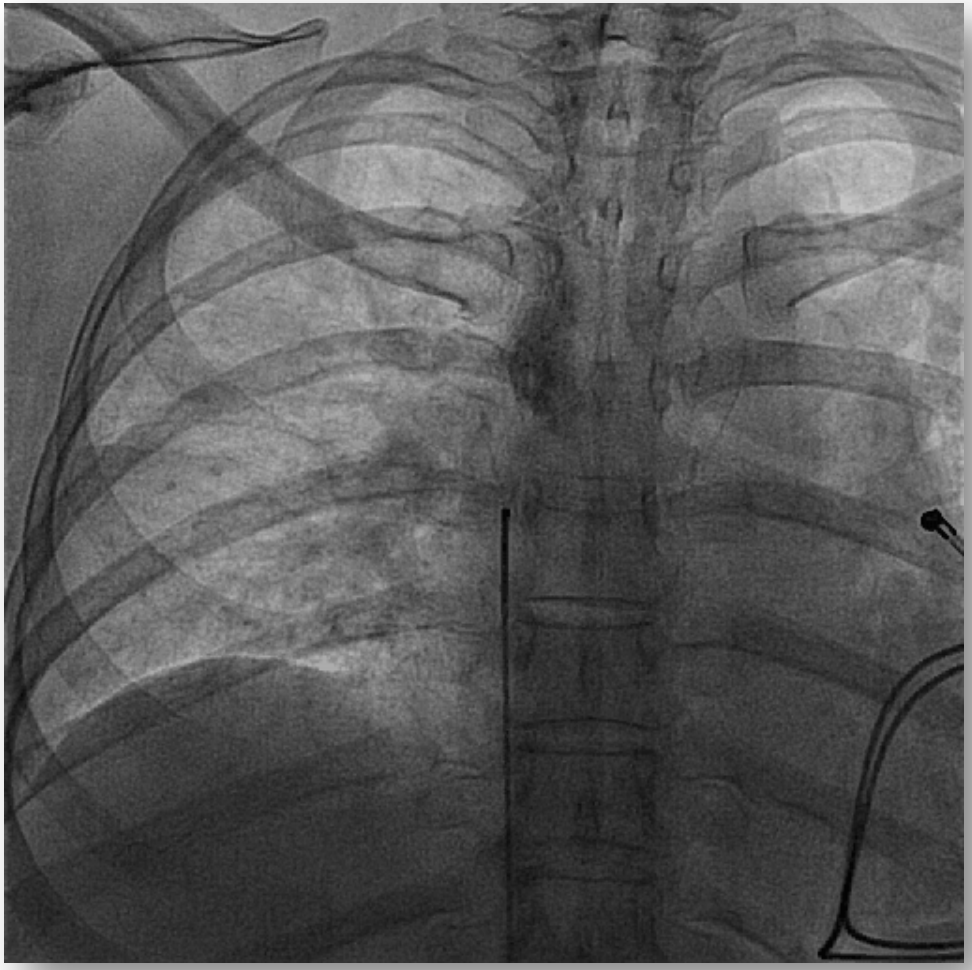

Interventional Device Implantation

Techniques for Overcoming Difficult Anatomy

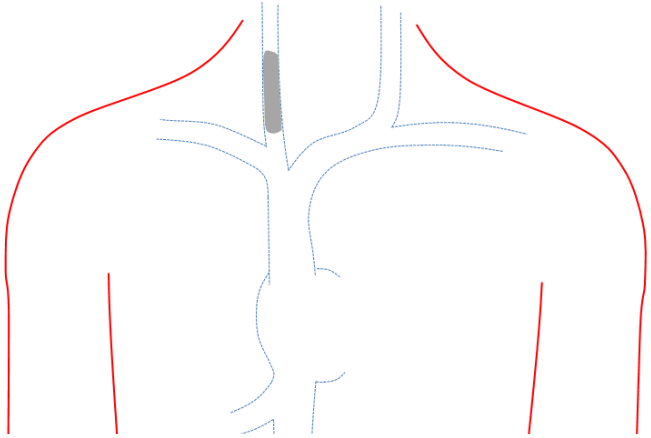

Type 1. IJ and/or SC occlusion

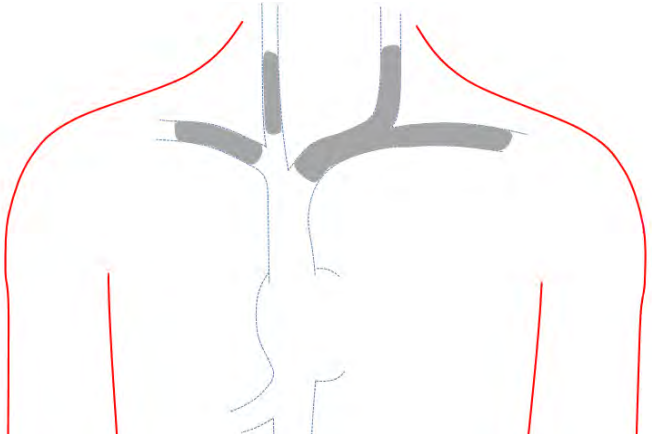

Type 2. Brachiocephalic w/ patent SVC

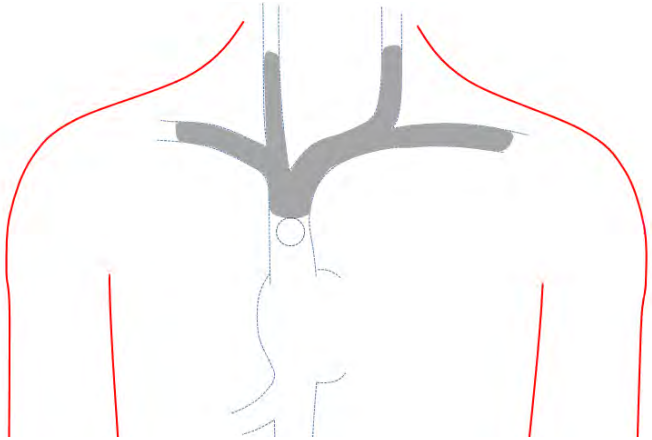

Type 3. SVC above azygos

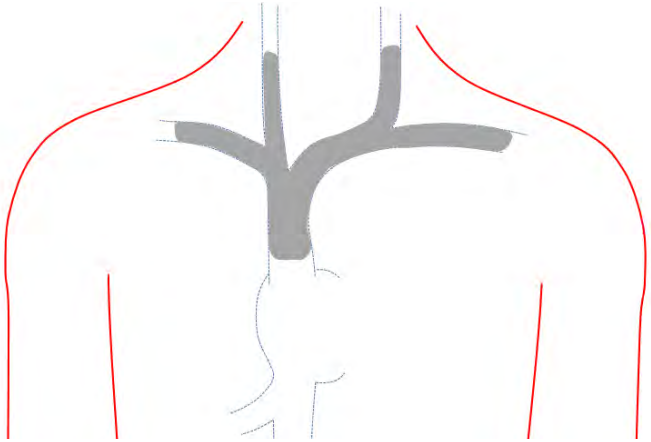

✓ **Type 4.** SVC below azygos

Angiography shows stump of SVC

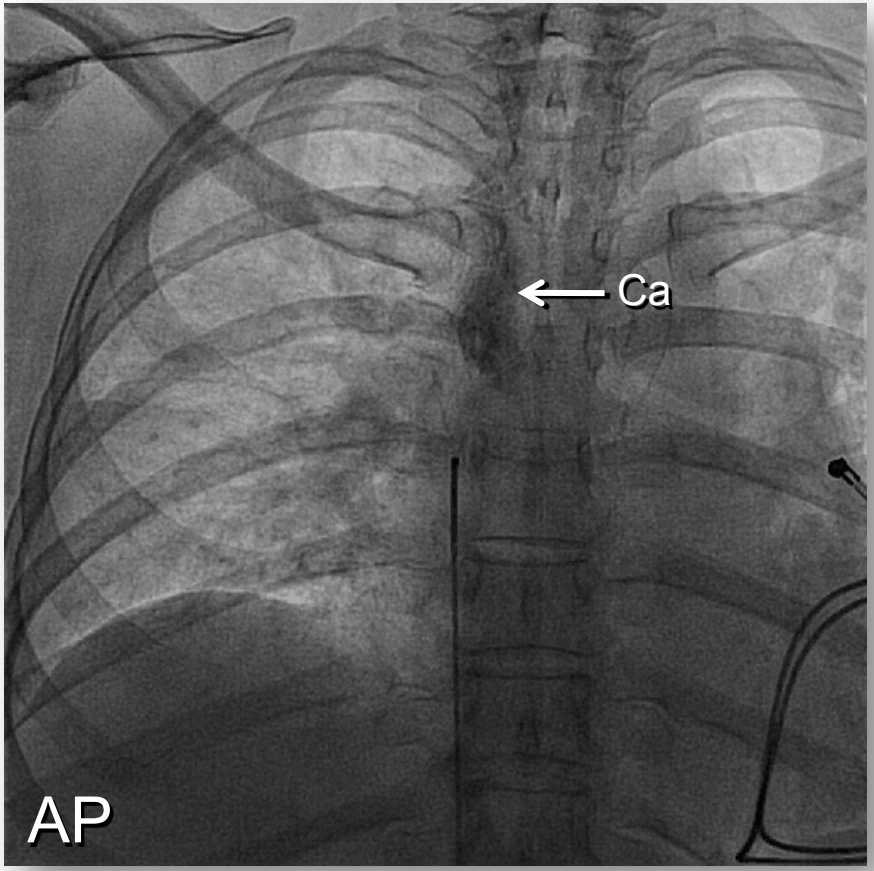

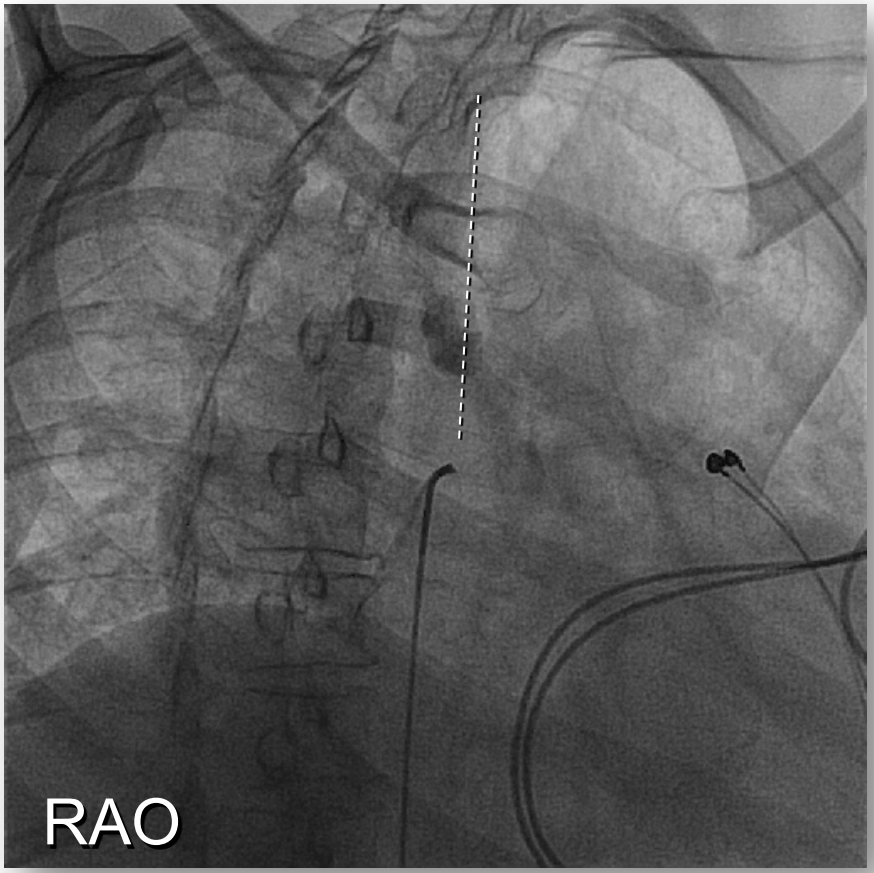

Blunt dissection to head of clavicle

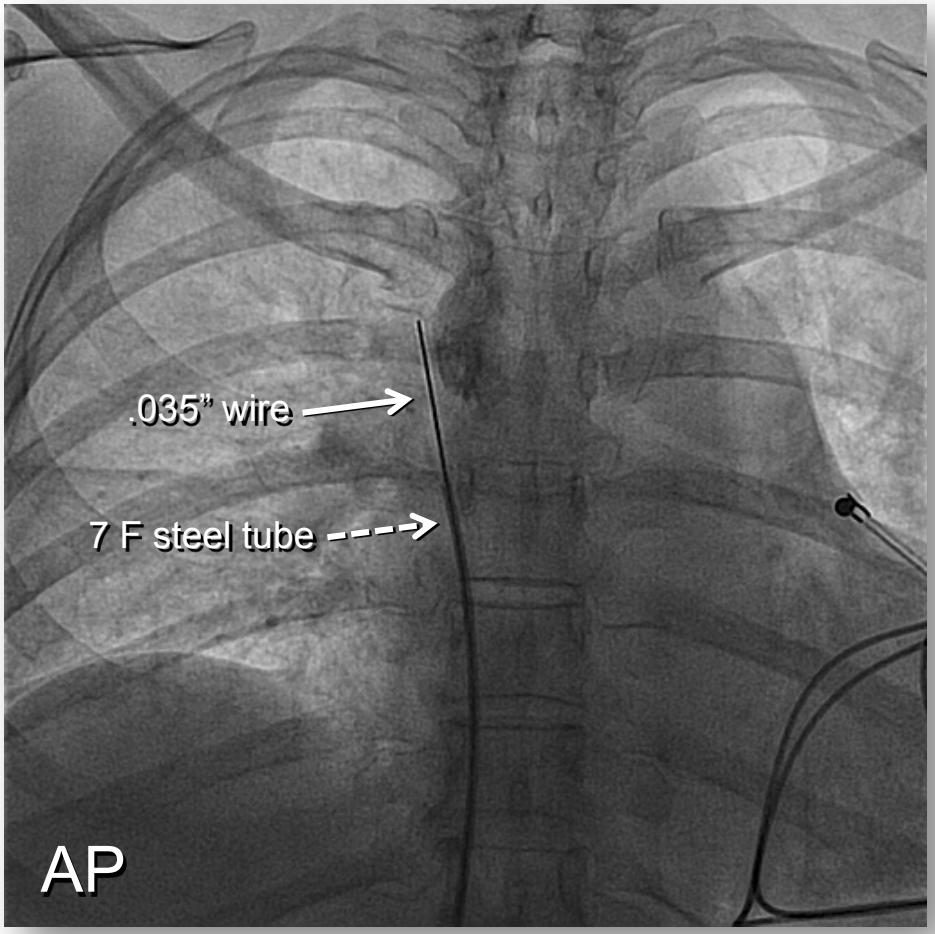

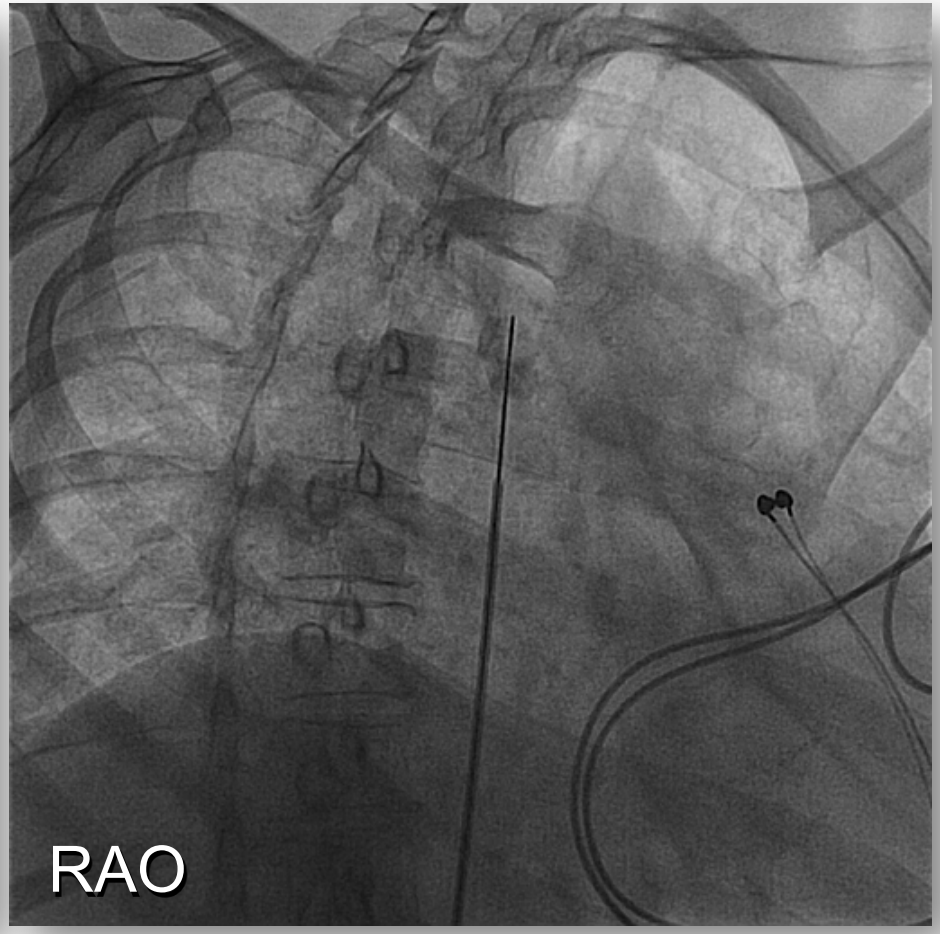

Inside-out puncture with sharp .018” wire

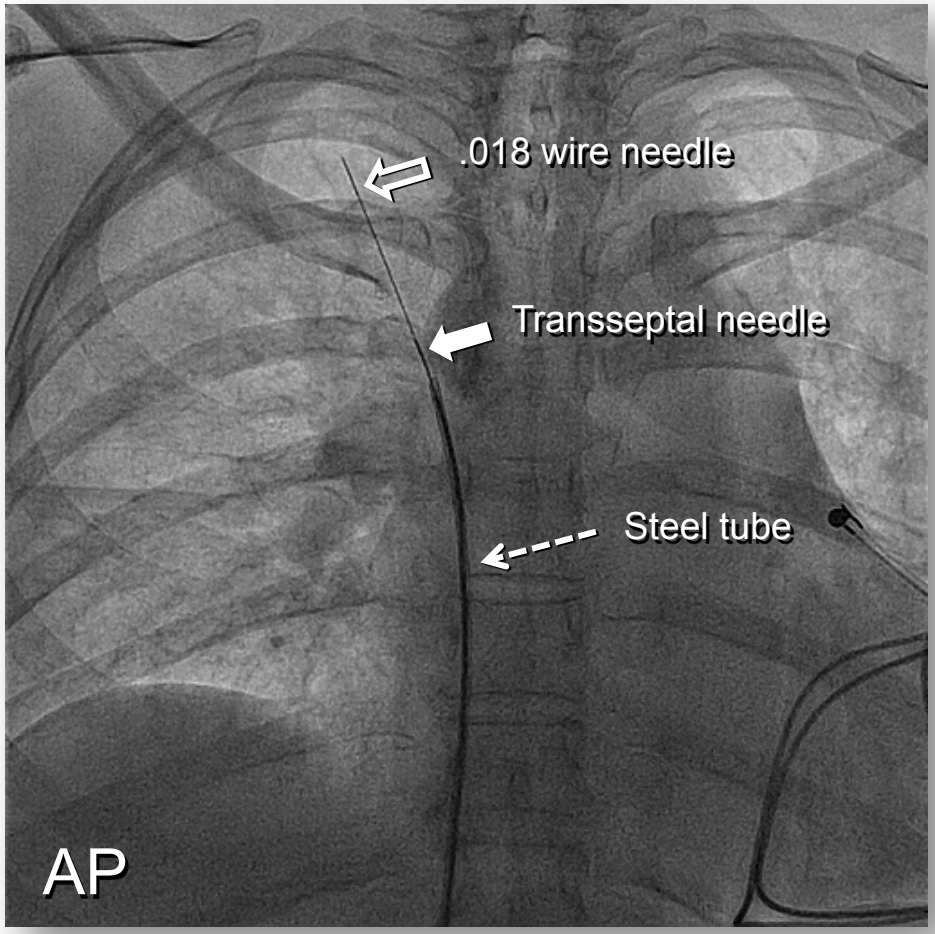

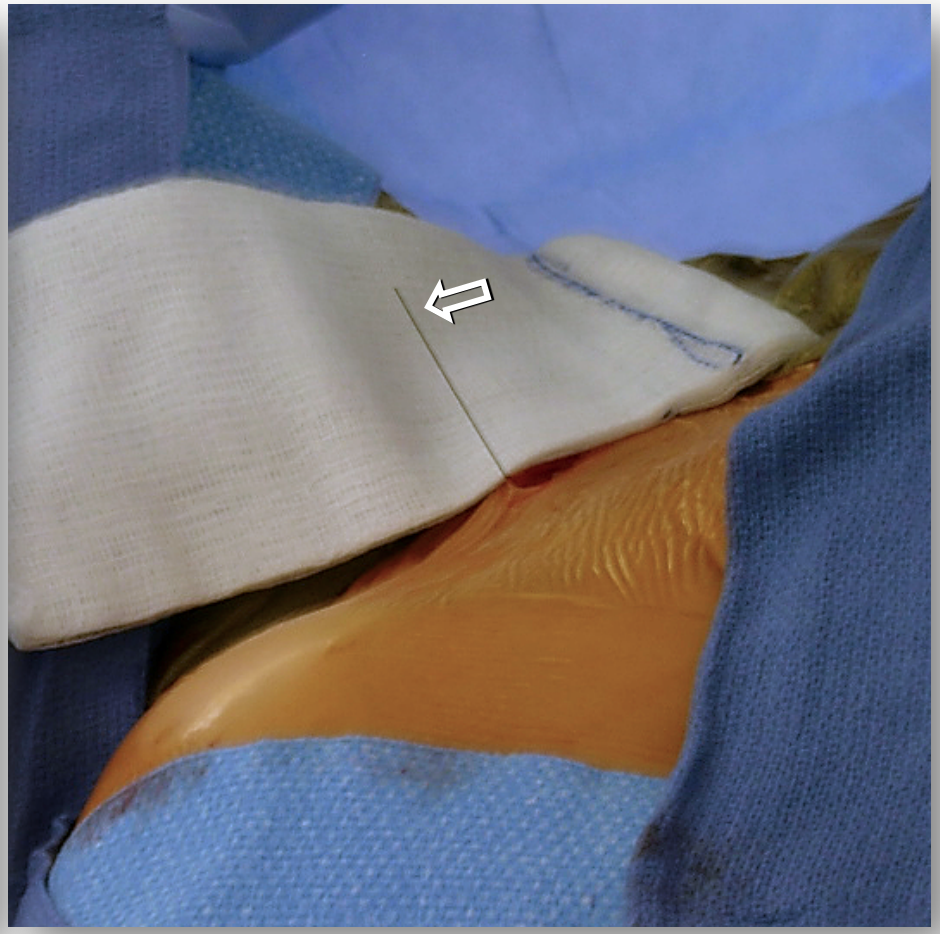

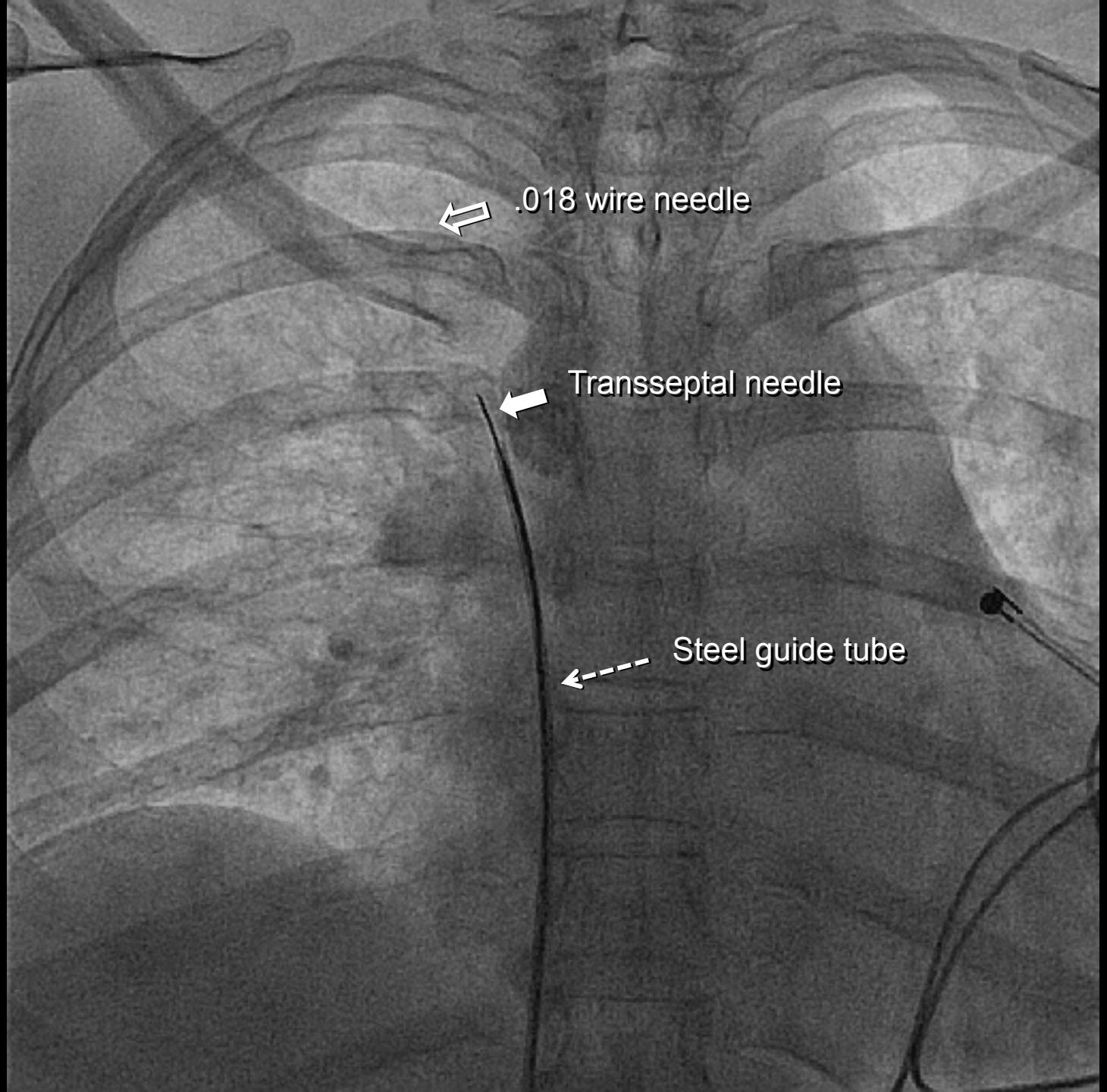
.018 wire needle
Transseptal needle
Steel guide tube

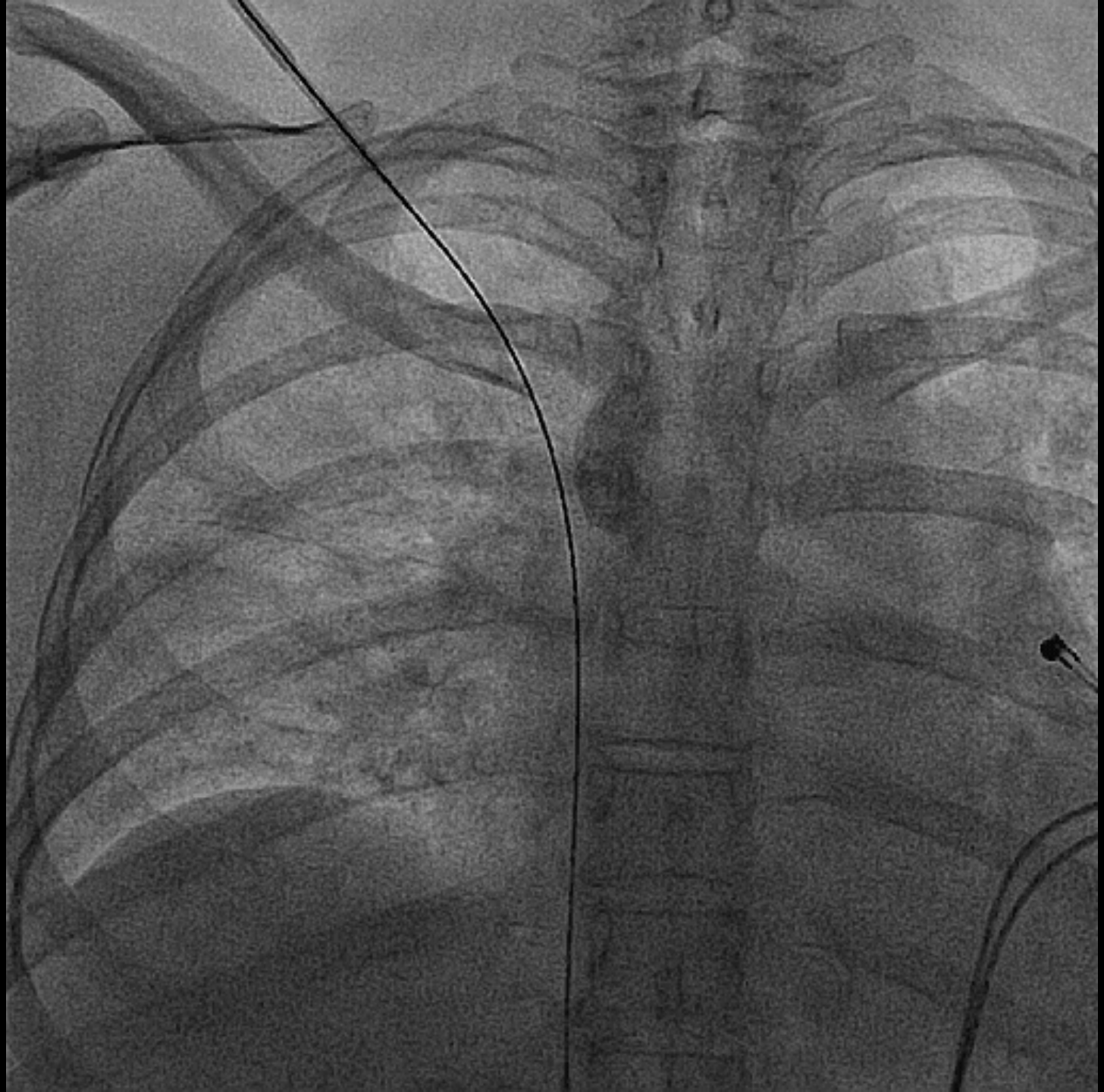

Place additional sheaths

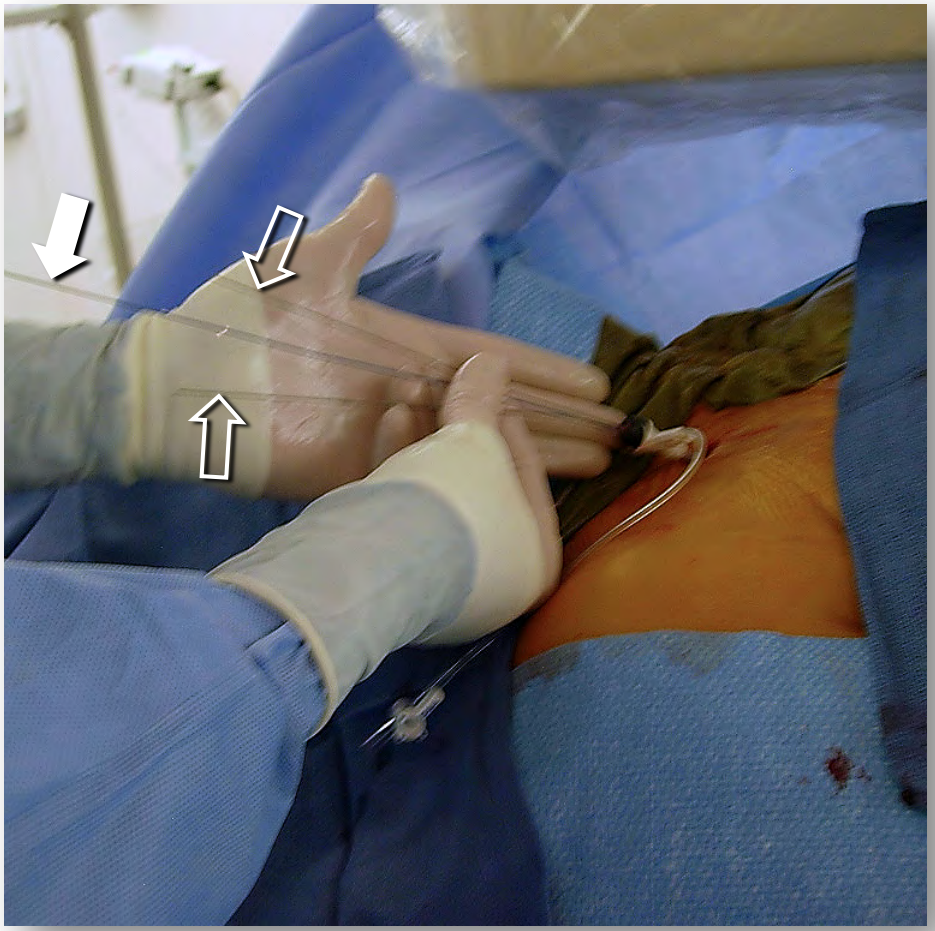

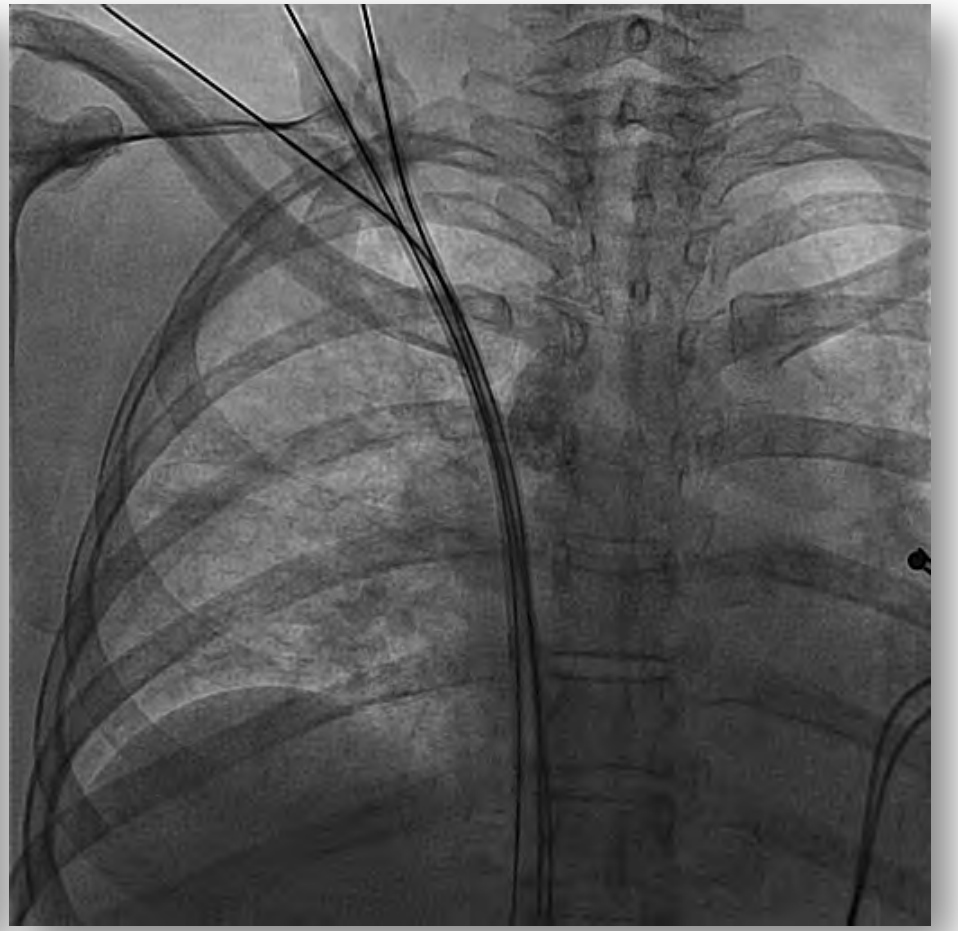

Pre-pectoral, subcutaneous implant

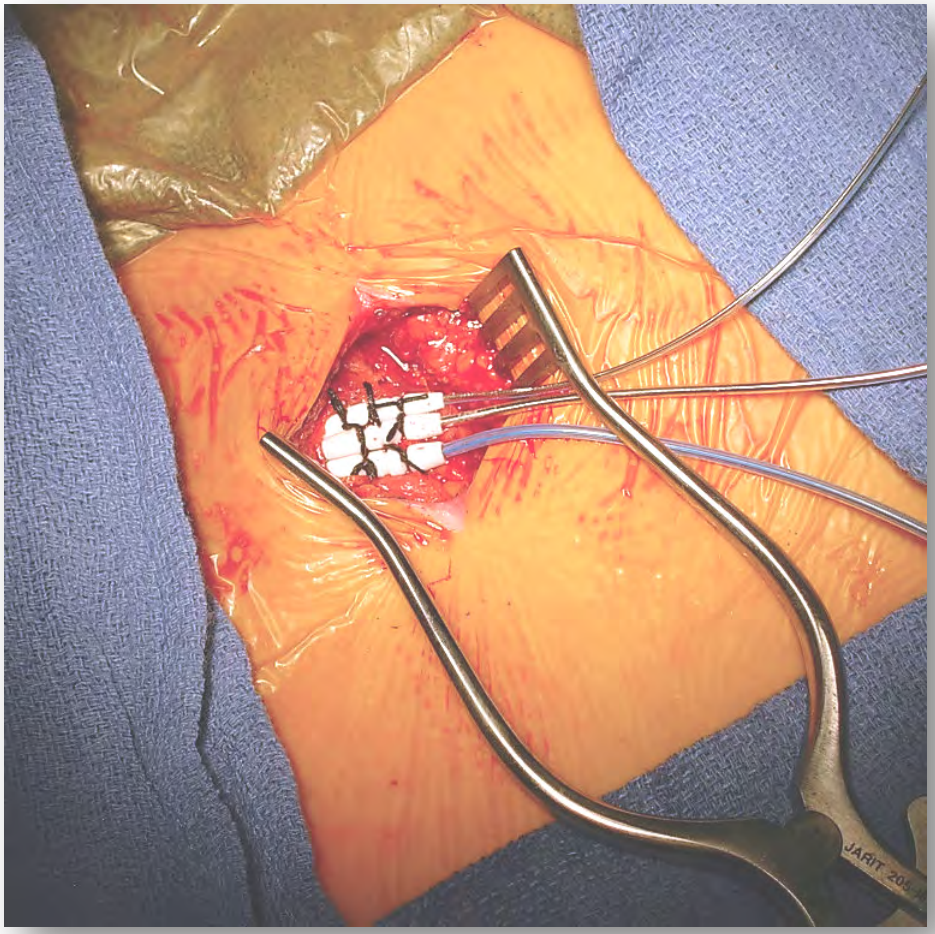

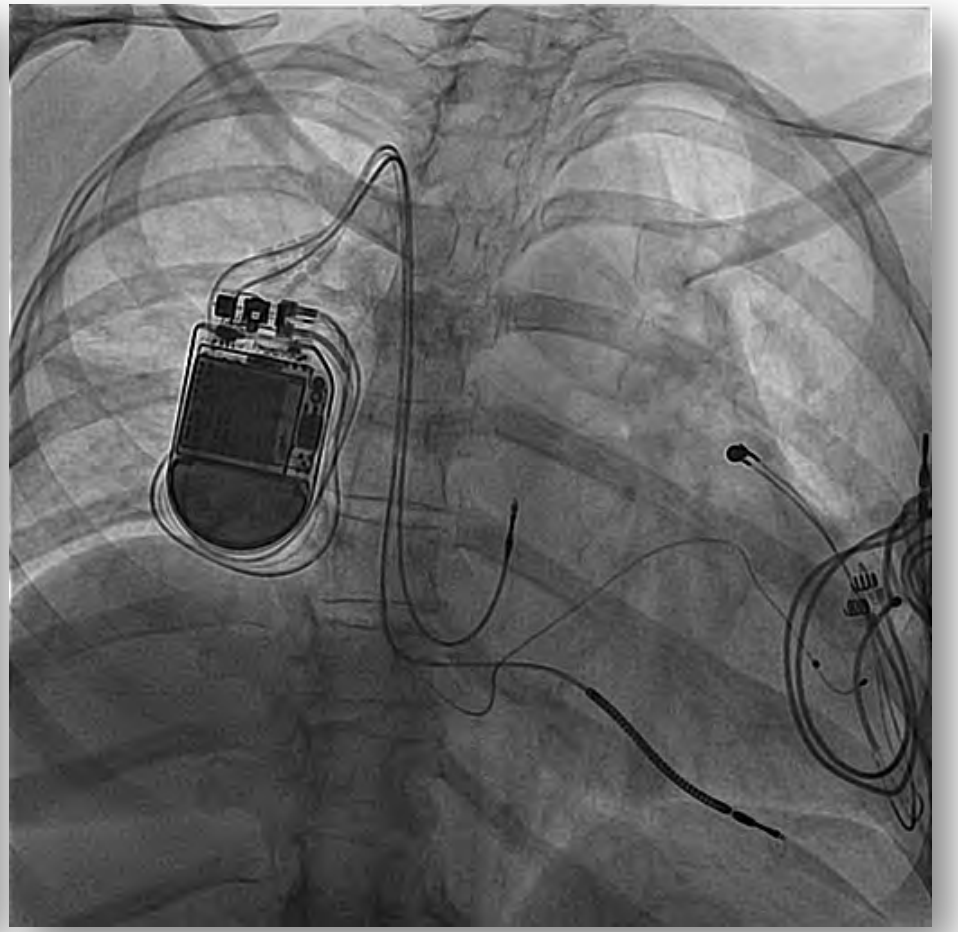

Size and bulk of multiple leads?

IOCVA for 31 French veno-veno ECMO cannula plus a 15 French tunneled dialysis catheter

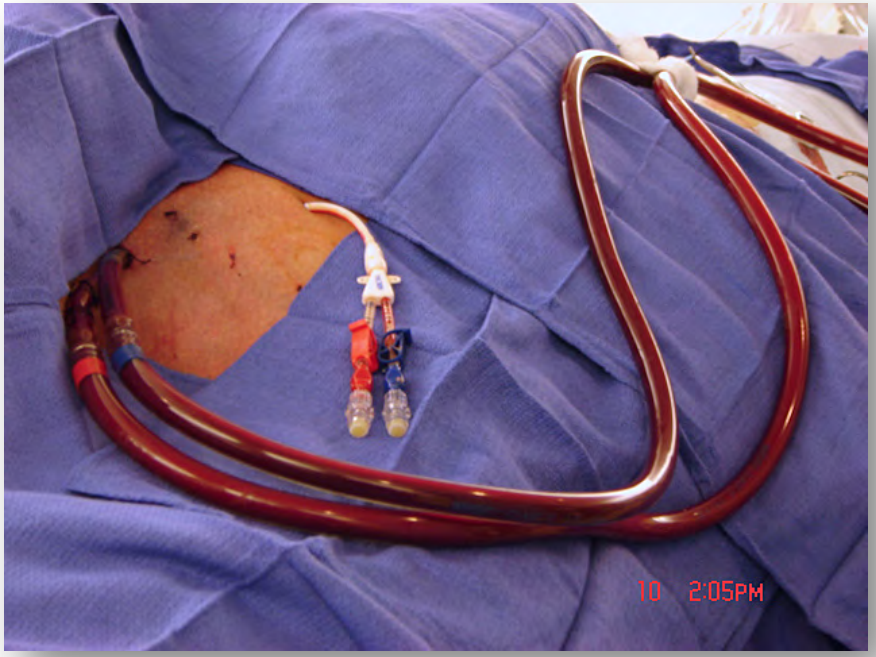

Comment on sheaths

- Largest sheath first
- 1-2 French larger than lead
- Retain sheaths until all leads are placed
- Long sheaths desirable
- Purse string suture

Case study #3: Right subclavian approach for CRT-D

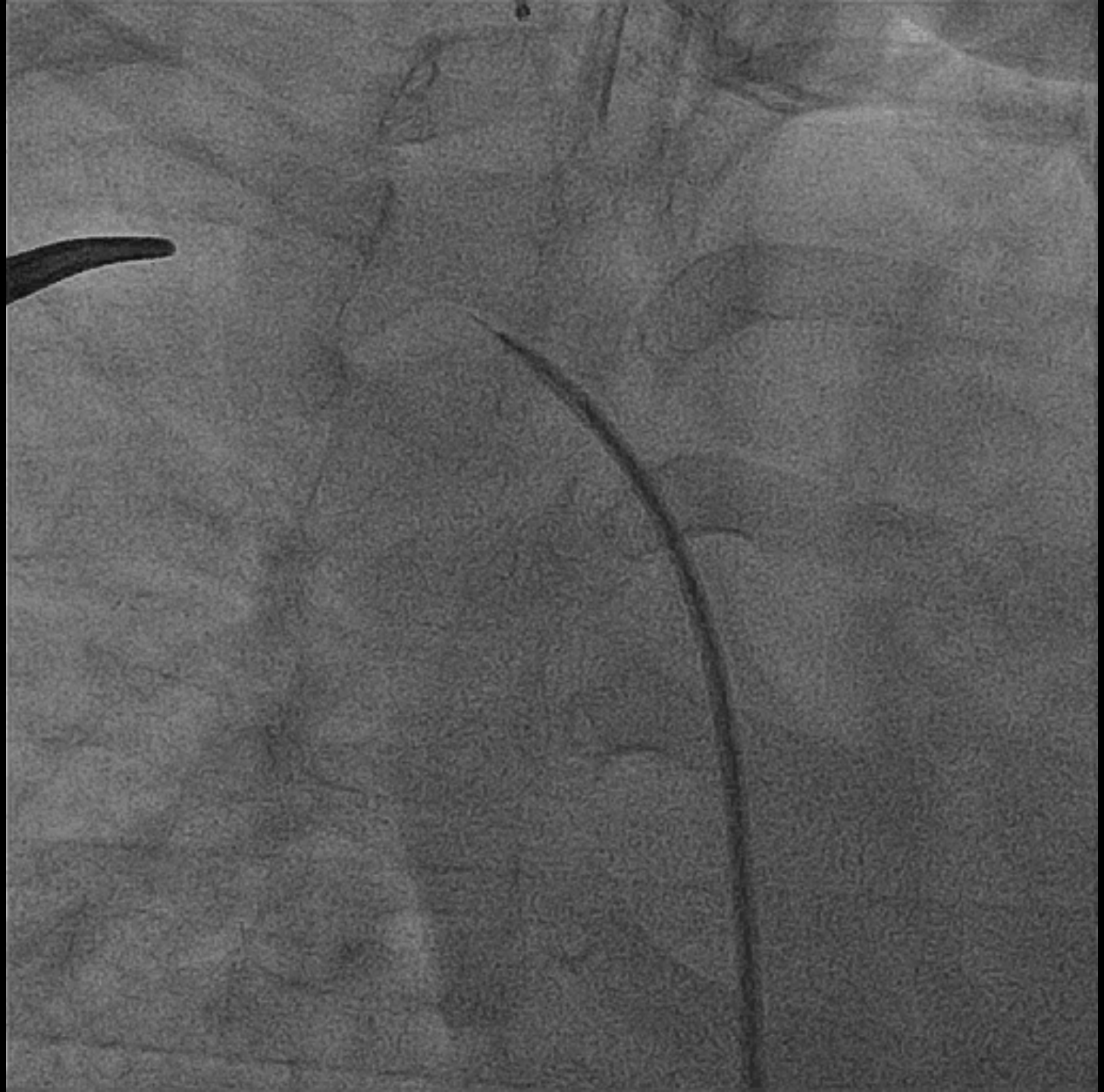

1. Skin markers

2. Subclavian IOCVA exit

3. Tunnel wire into pocket

4. Pull dilator

Comments on subclavian approach

Compared to supraclavicular…

- Narrow rib-clavicle target window
- More difficult to aim
- More difficult to control torque and exit angle
- Concern about proximity to great arteries
- More challenging, less experience

Case study #4: Right subclavian approach for CRT-D

- 48 year old woman with nonischemic CM
- Low EF, wide LBBB, class III-IV
- Two mechanical valves
- Bilateral SC and BC occlusions
- Multiple previous heart operations
- Surgeons declined reoperation for epicardial

Exteriorized .018” needle wire

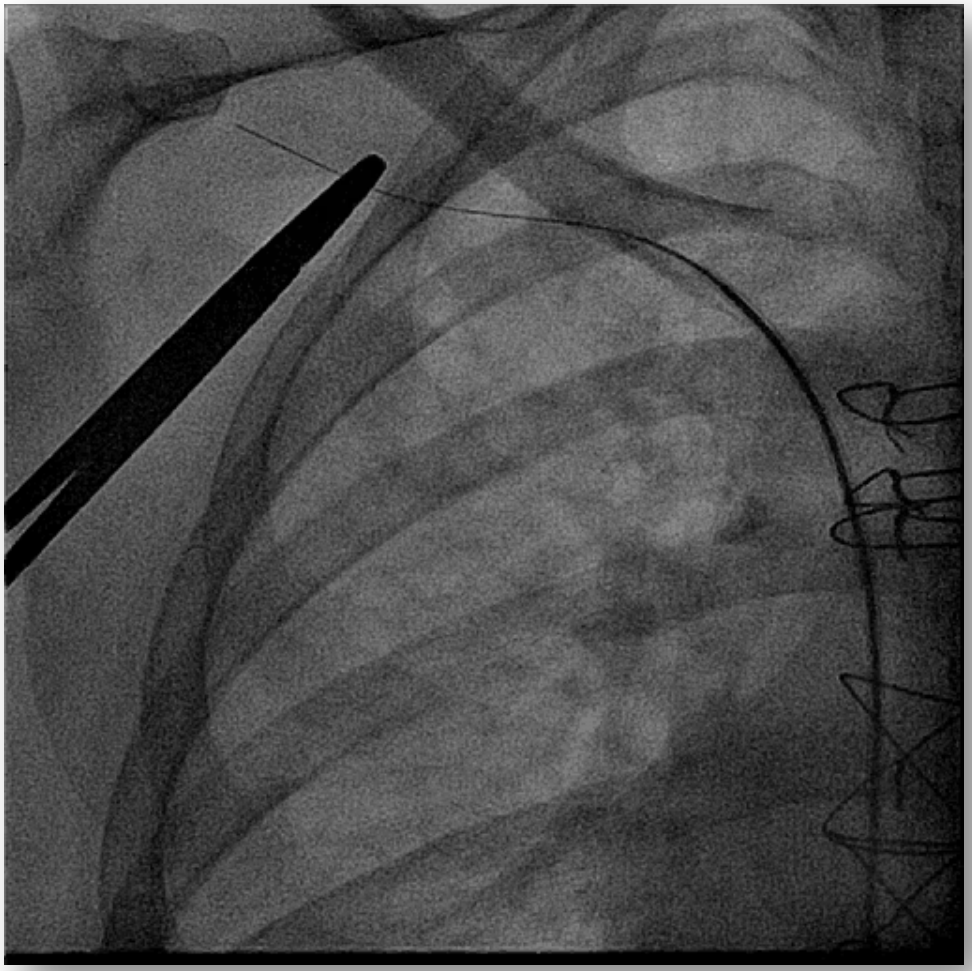

Pull first sheath down

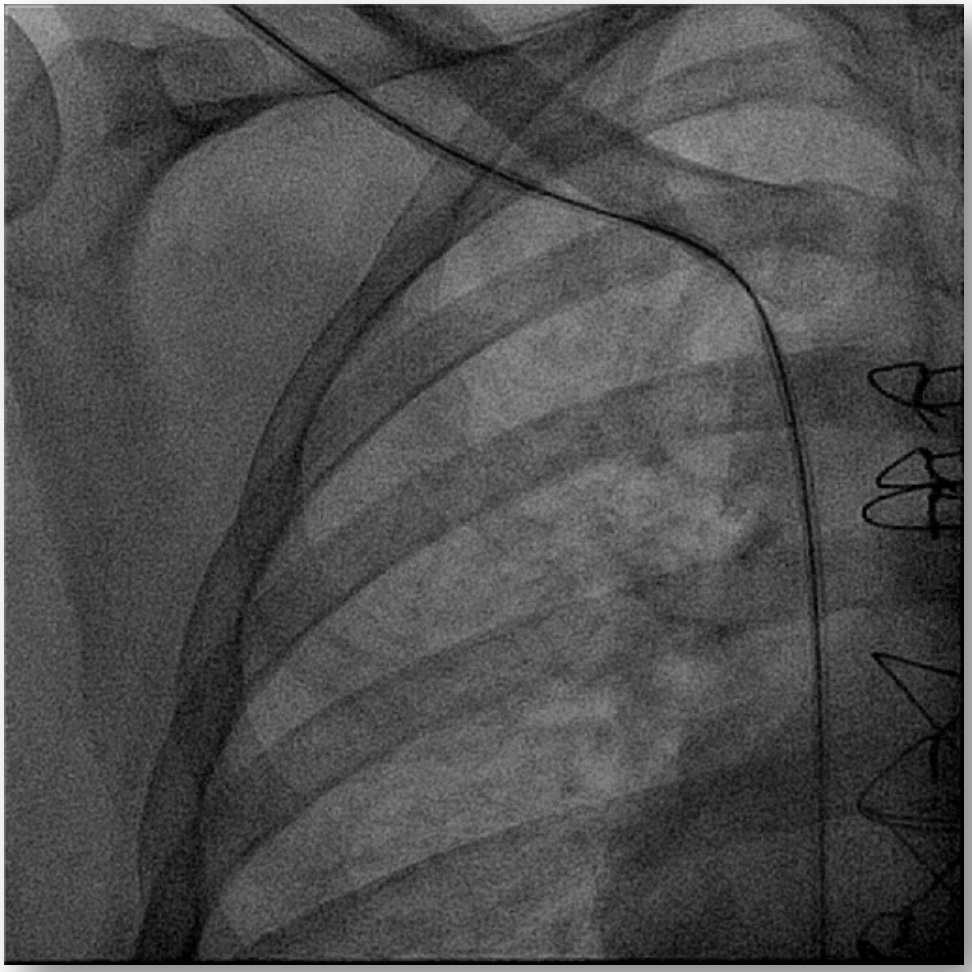

Pull second sheath down

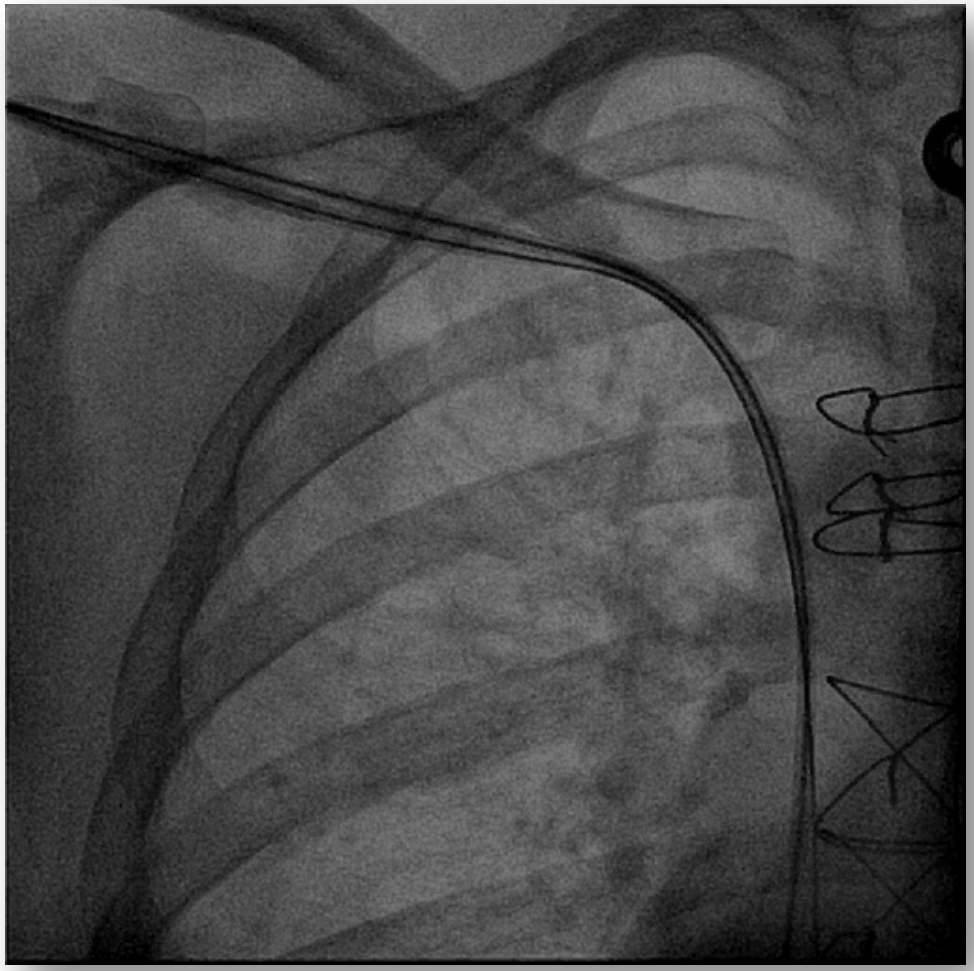

Pull third sheath down

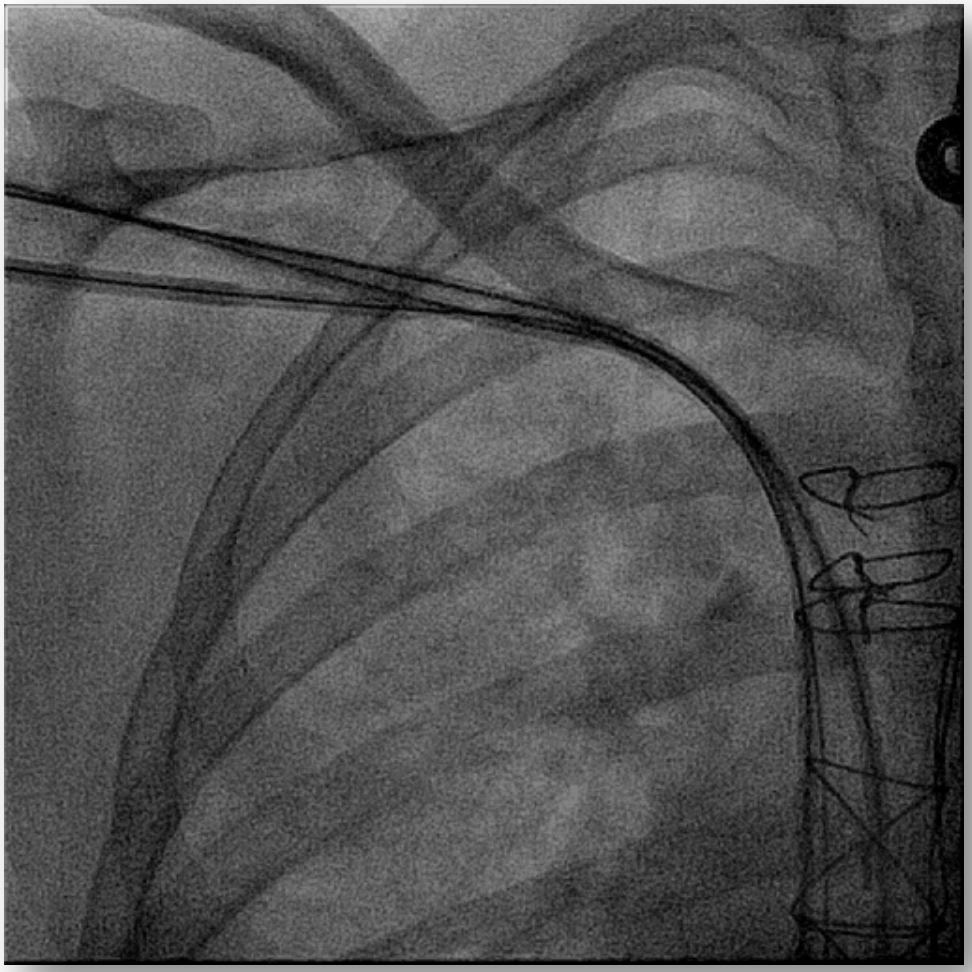

Balloon-occluded CS venography

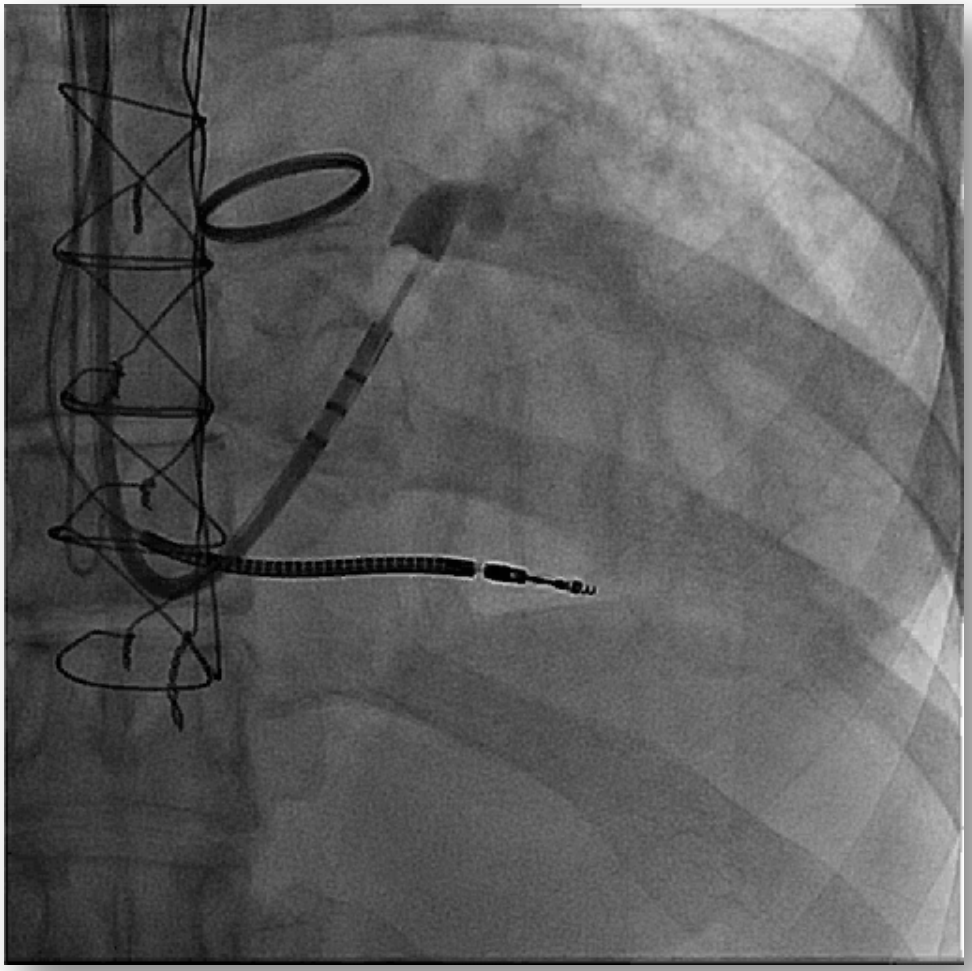

Conventional device implant

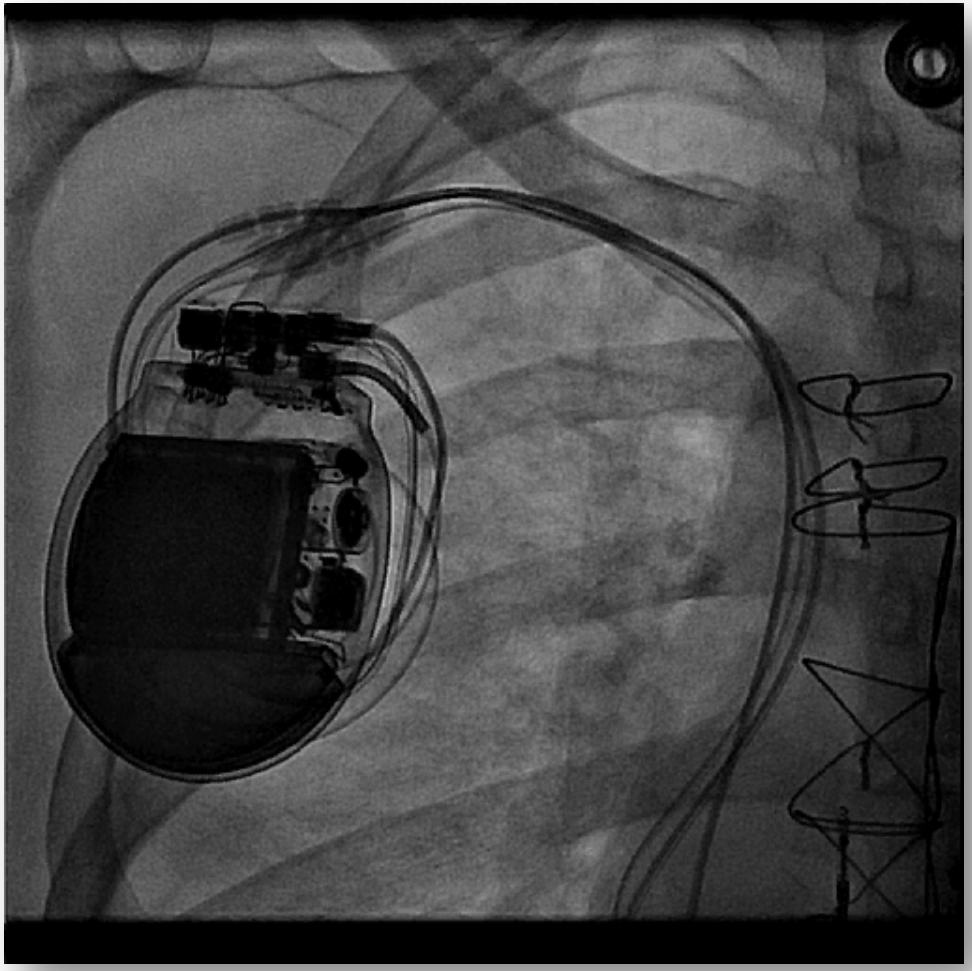

Case study #5: Left subclavian IOCVA for dual chamber ICD

- 21 year old female with chronic renal failure
- Non-ischemic CM, EF <25%, arrhythmia indication
- Chronic, total occlusion of LSC & brachiocephalic veins due to previous hemodialysis access
- Failed attempts at interventional recanalization (antegrade and retrograde)
- Dialysis dependent—essential to preserve right sided veins for AV fistula

Venogram confirms occlusion

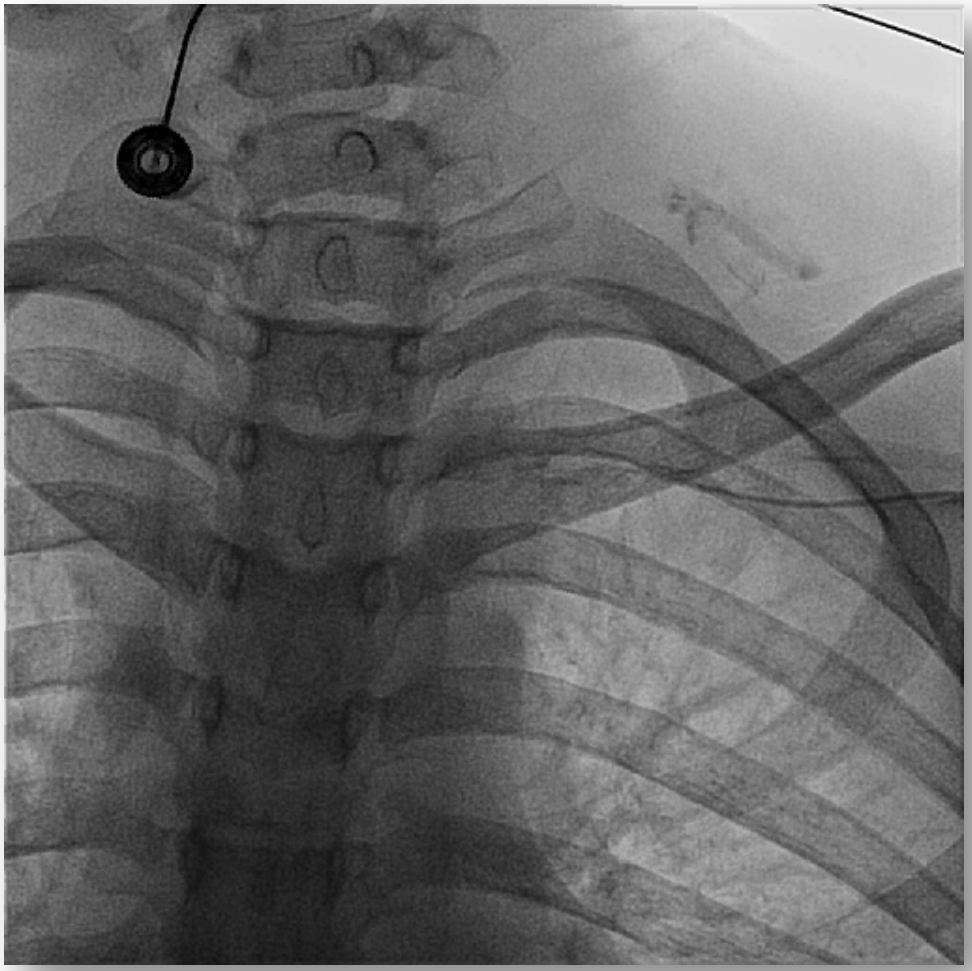

SVC angio defines central extent

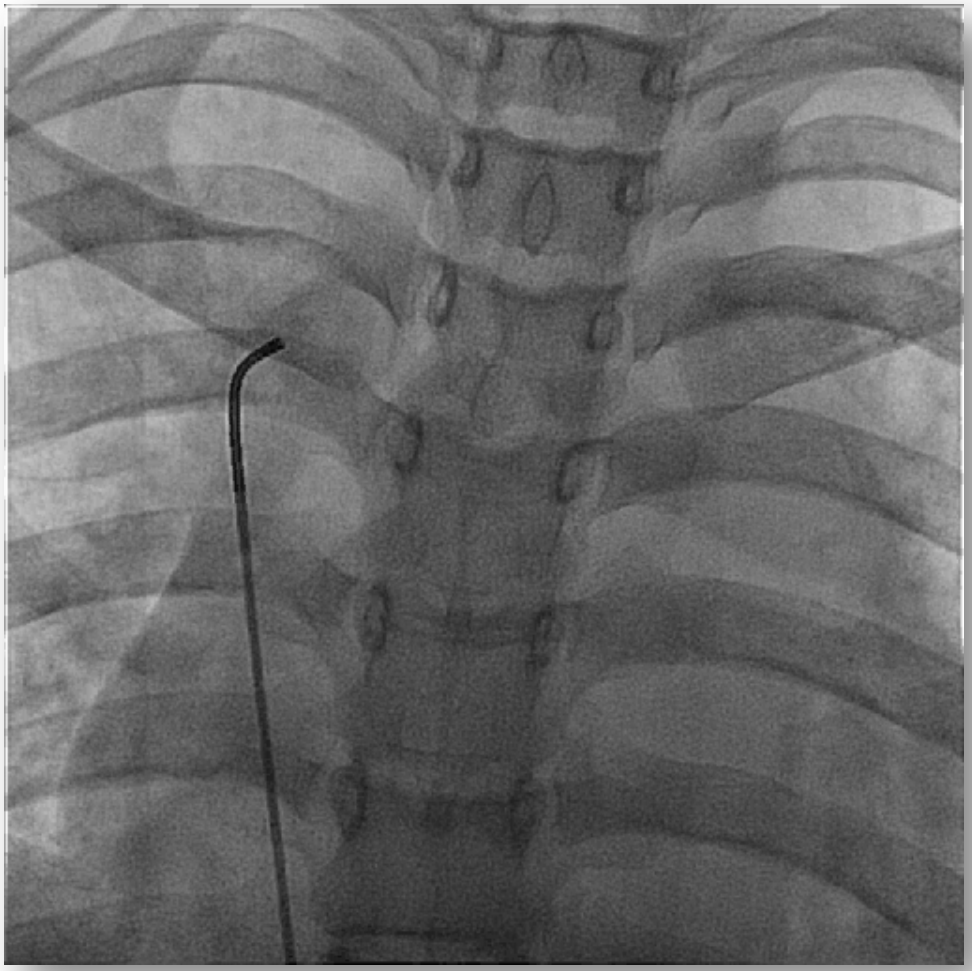

Align dilator with target needle

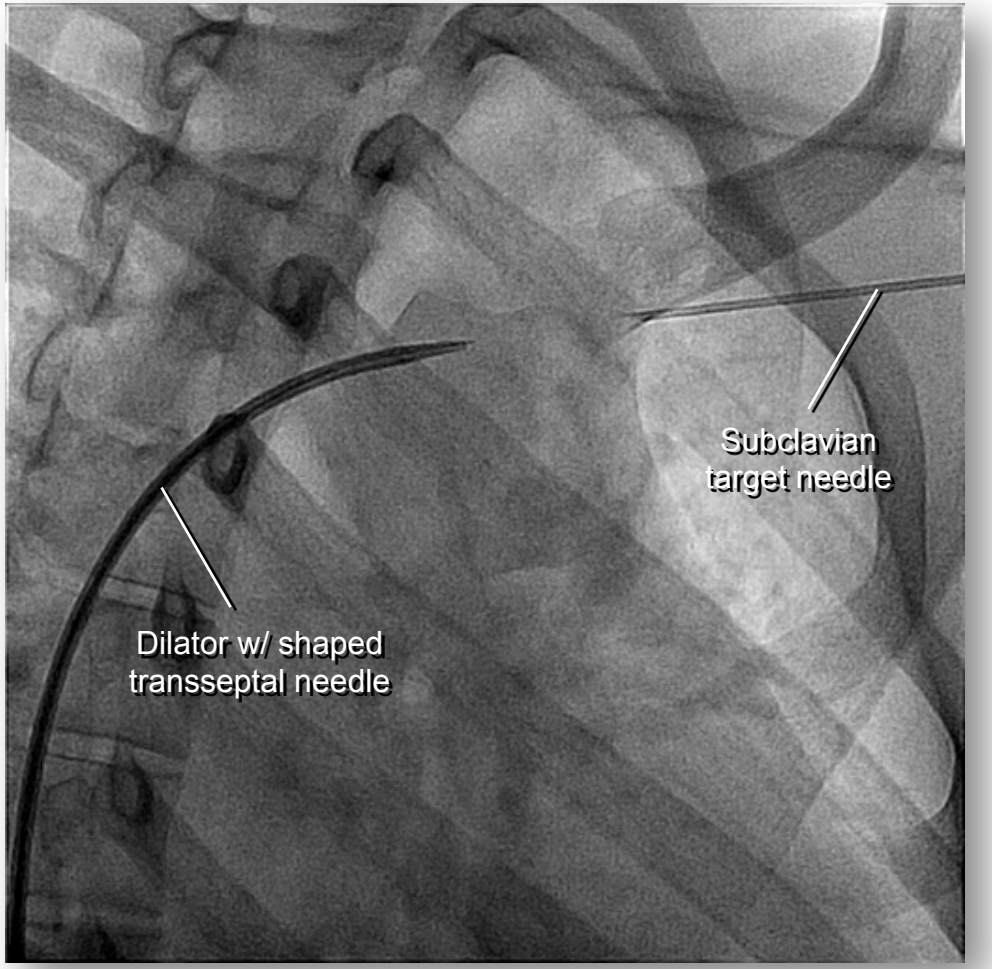

Puncture inside-out

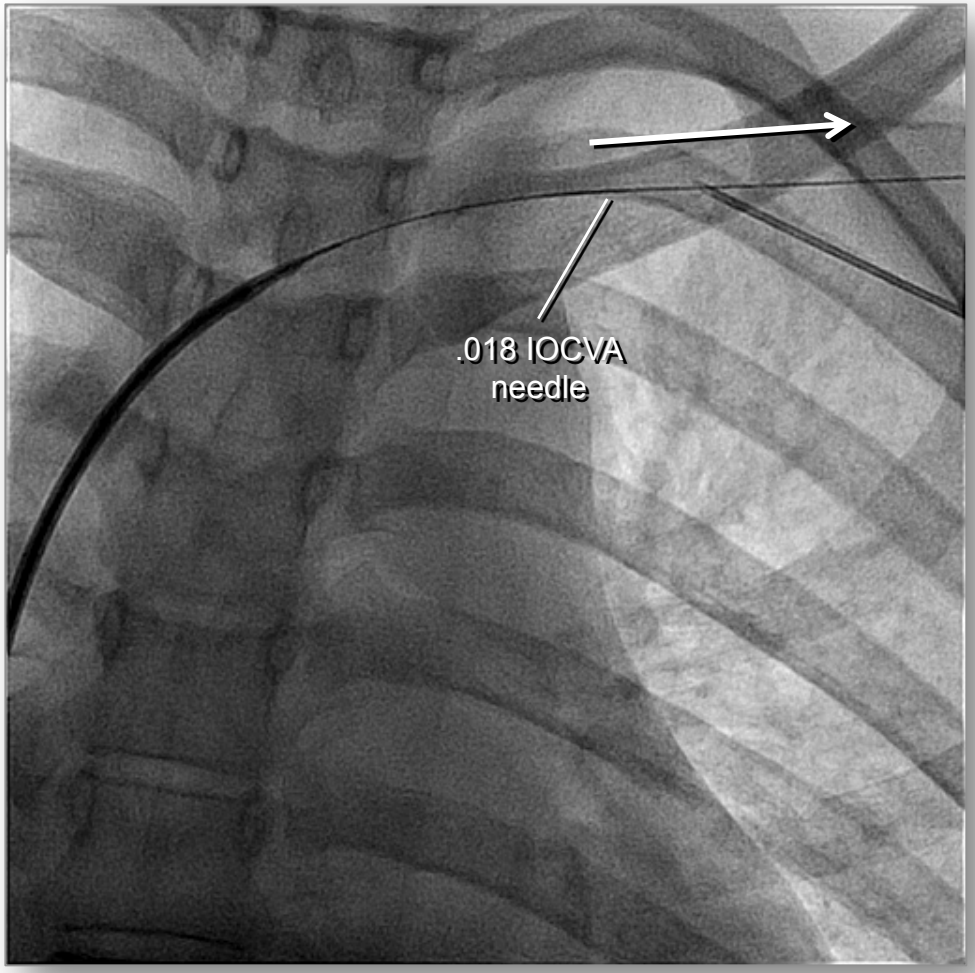

Pull dilator upward to exteriorize

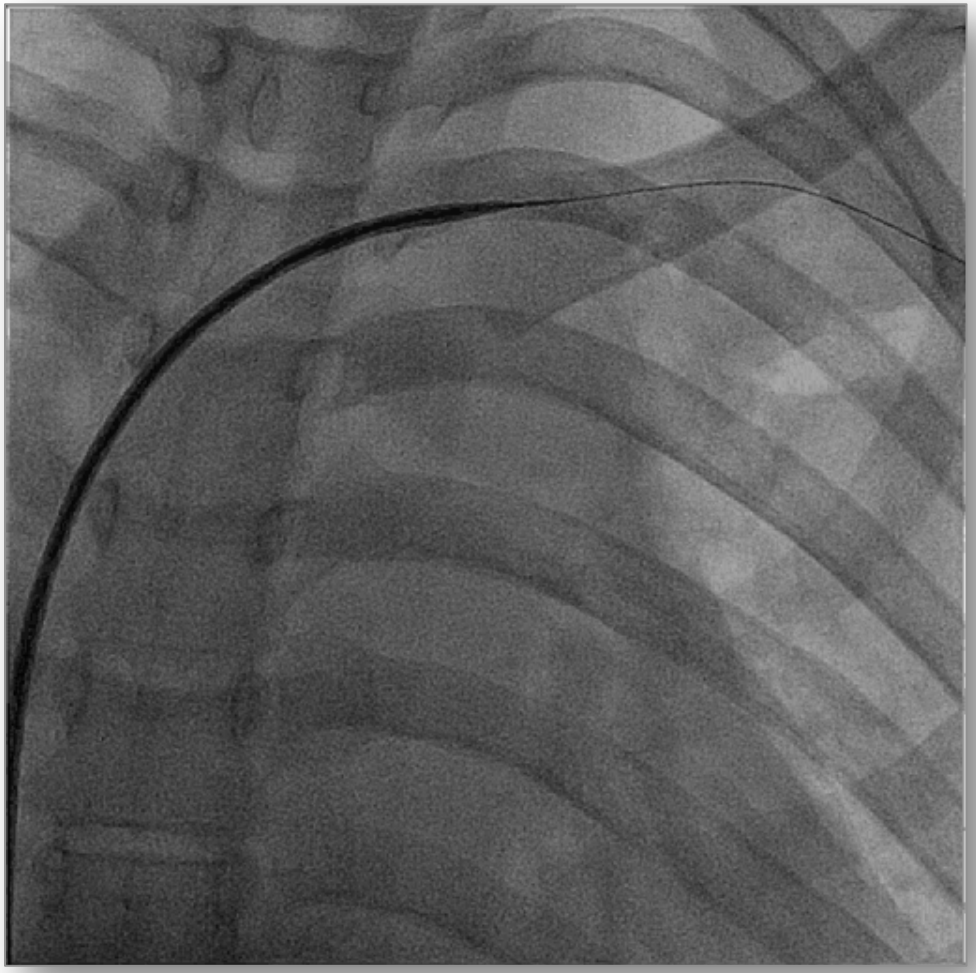

Pull introducer sheath into RA

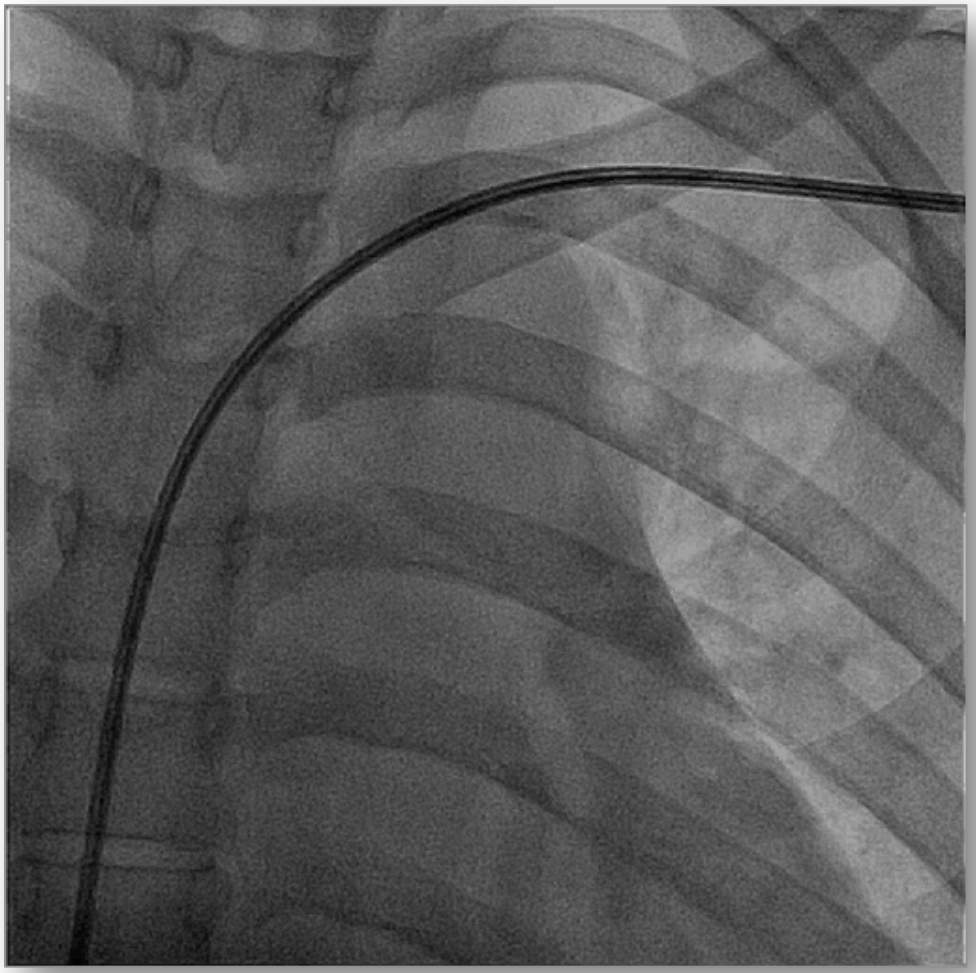

Completion fluoroscopy

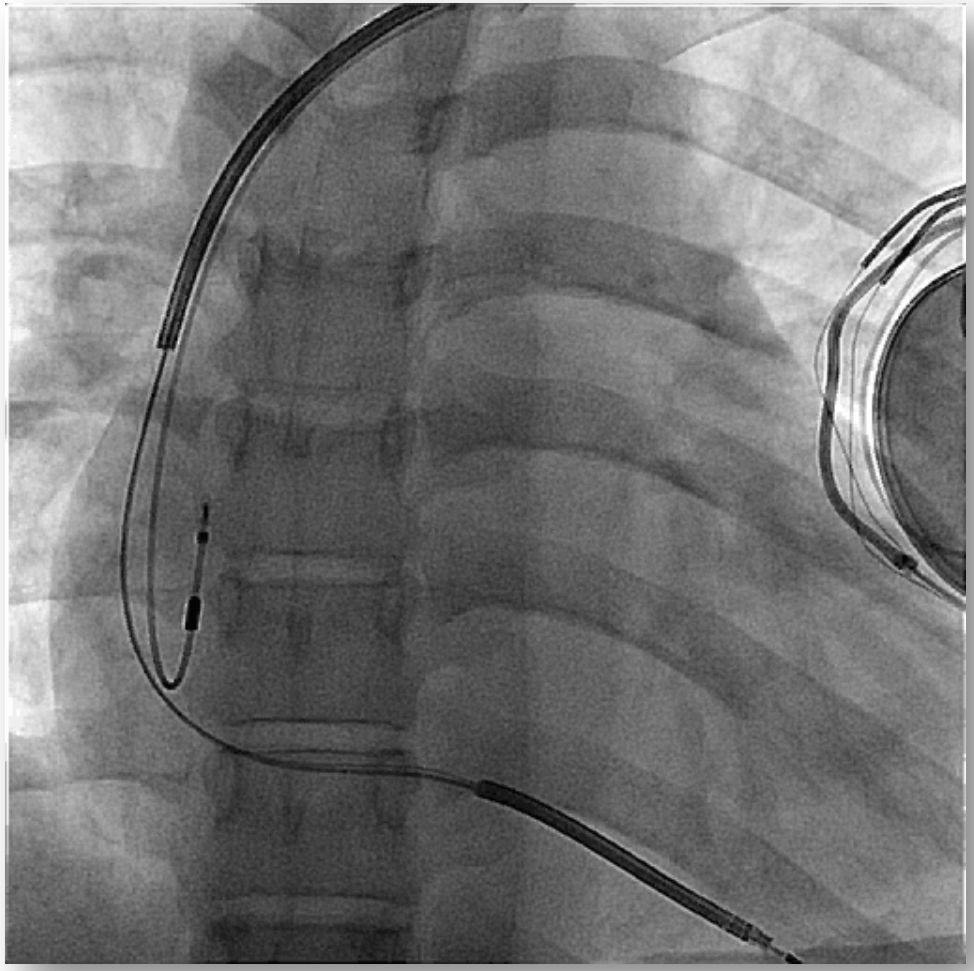

Summary of experience to date

- 116 IOCVA procedures
- No technical failures
- No immediate complications
- One delayed pocket hematoma associated with excessive anticoagulation
  - Multiple mechanical valves
  - During transition from heparin to warfarin
  - Hematoma decompressed into right pleural space

Device types (n=116)

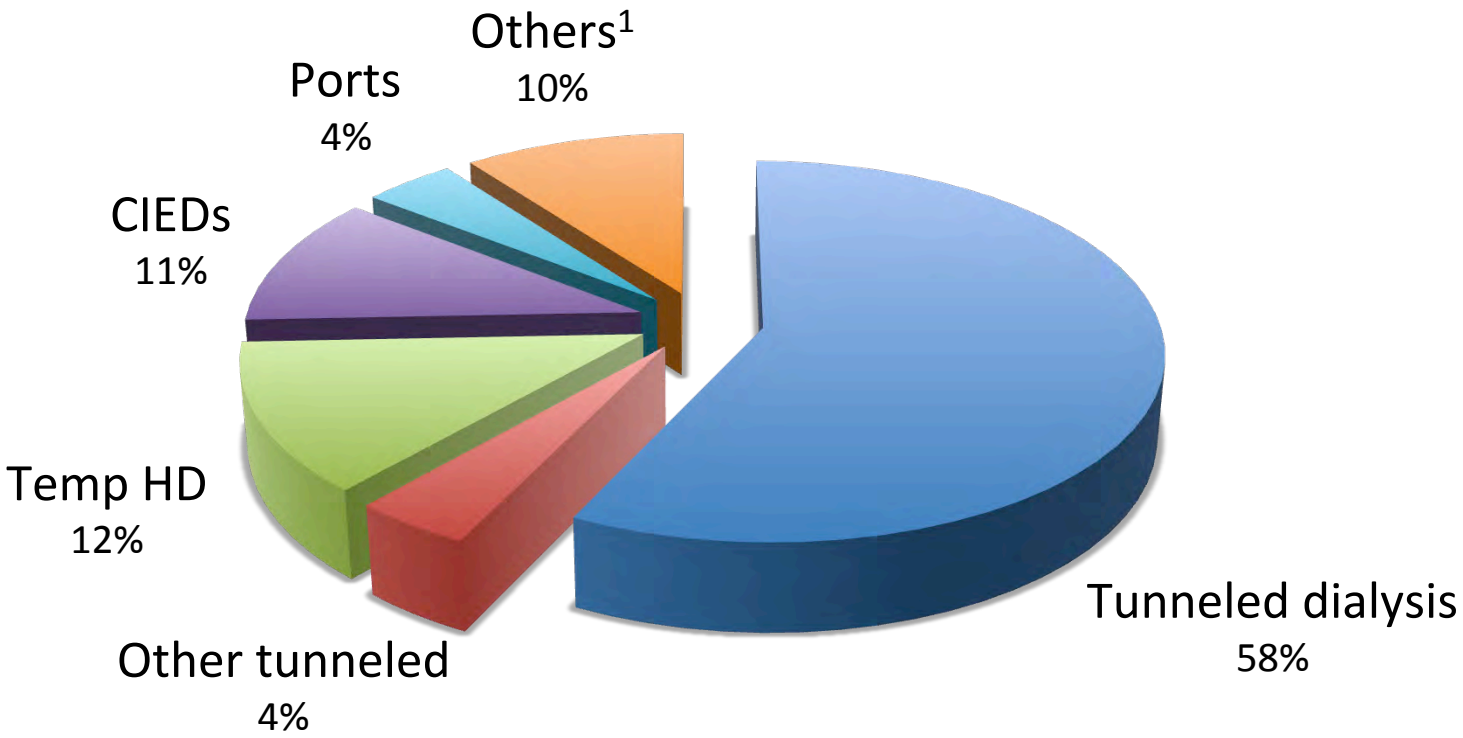

1. Includes temporary infusion catheters, heart and liver biopsies, ECMO, and structural heart interventions

Type of central venous occlusion

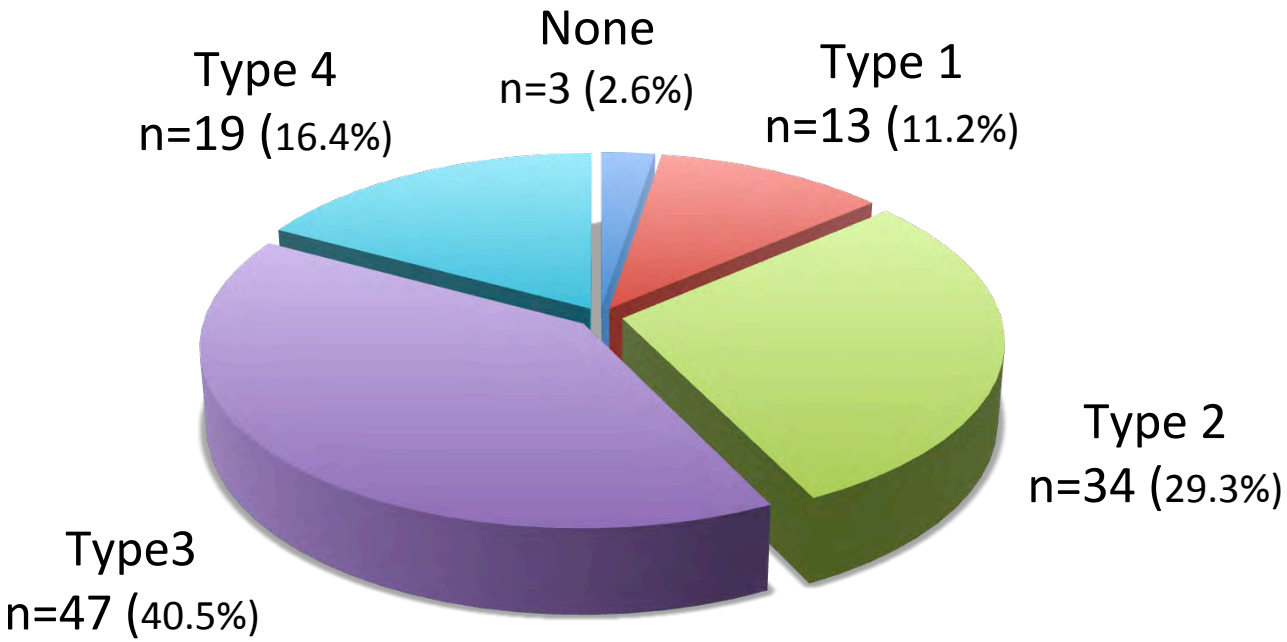

1. Unable to obtain conventional access due to trauma, immobilization, and/or other local factors

Repeat procedures

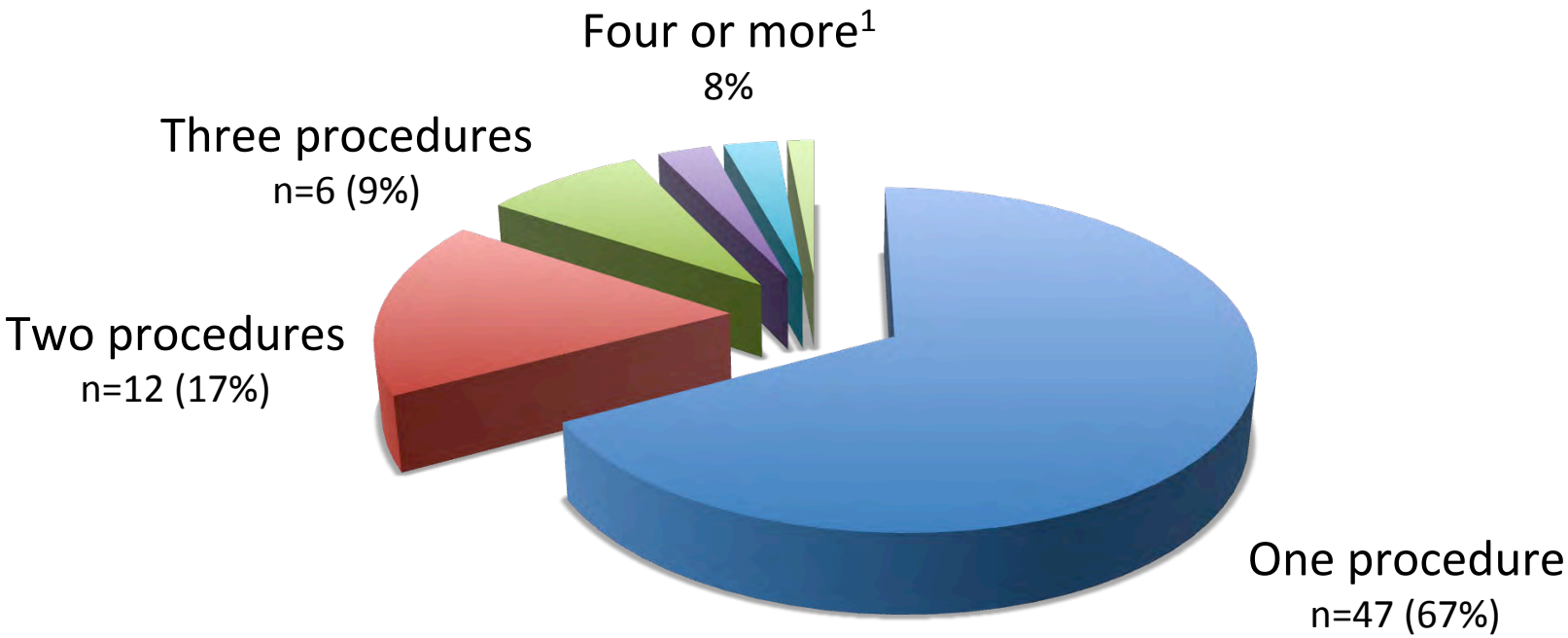

Entry sites

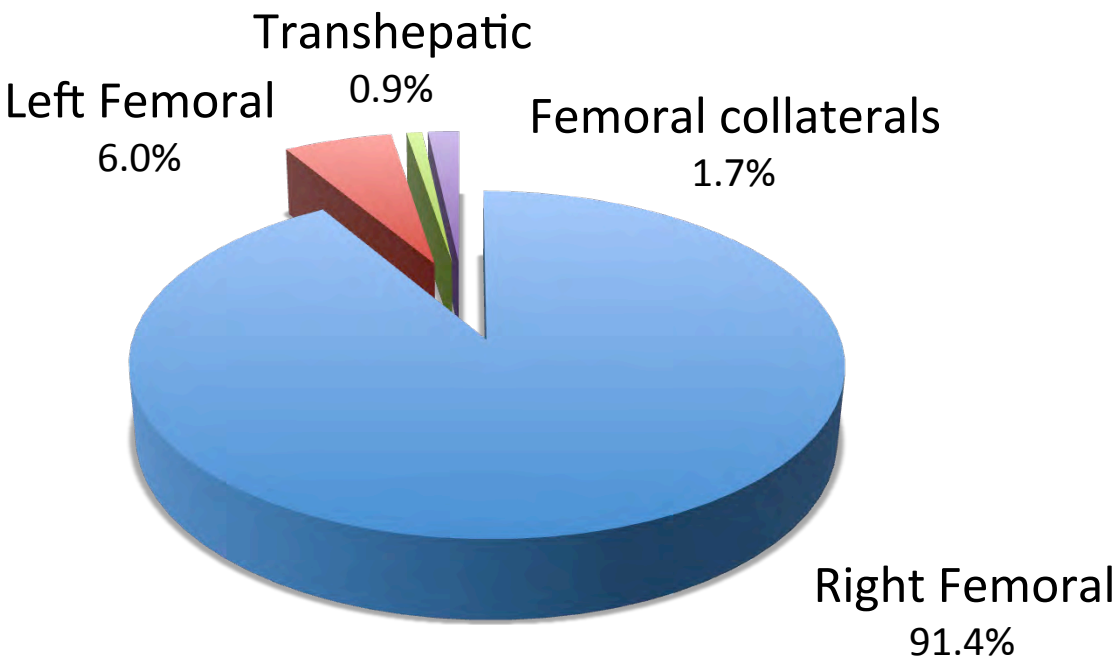
Transhepatic
0.9%
Left Femoral
6.0%
Femoral collaterals
1.7%
Right Femoral
91.4%

Exit sites

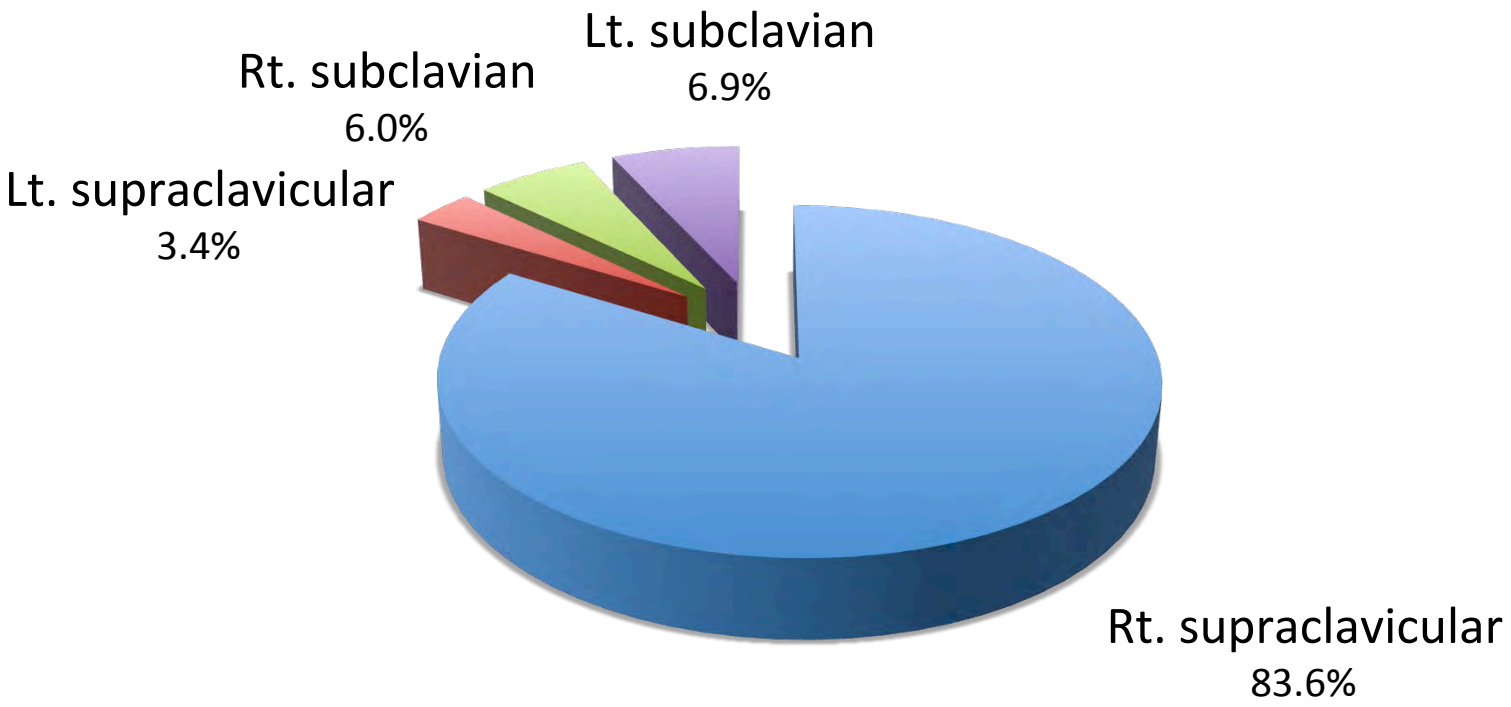
Lt. subclavian
6.9%
Rt. subclavian
6.0%
Lt. supraclavicular
3.4%
Rt. supraclavicular
83.6%

IOCVA fluoro time by type of occlusion(n=116)

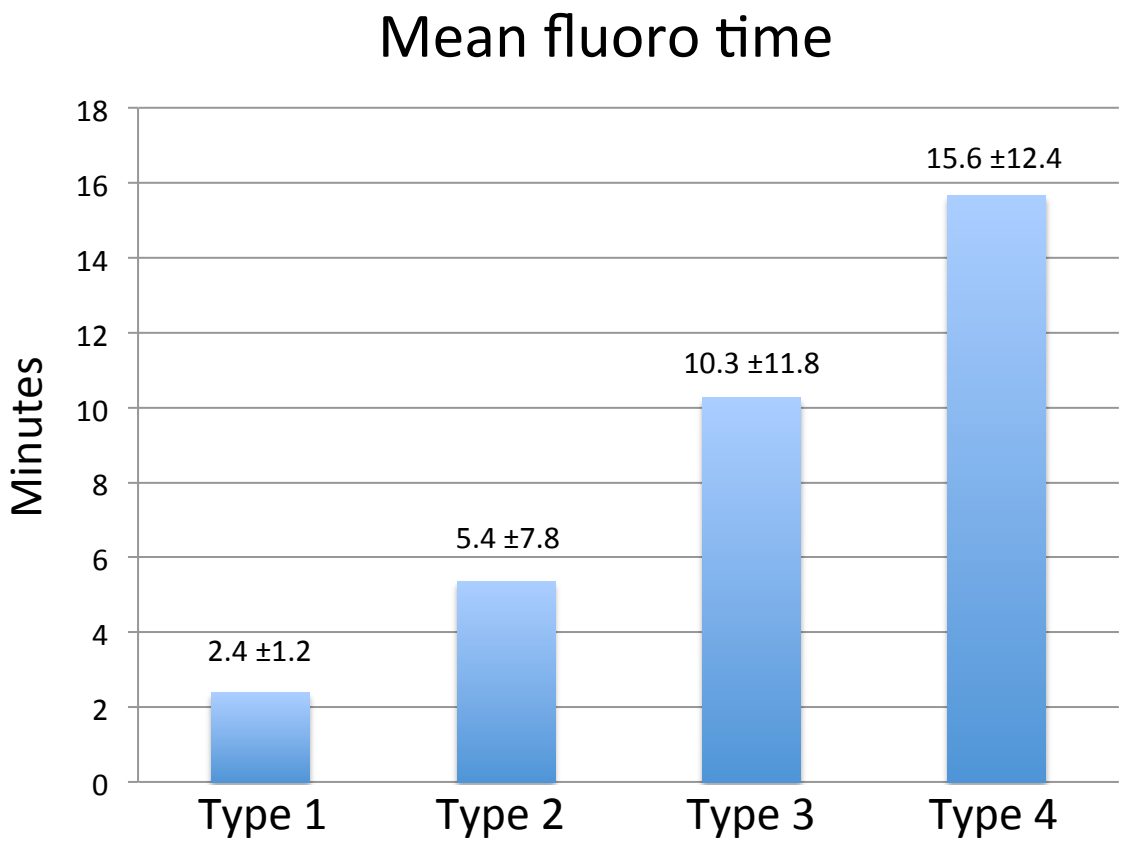

Initial experience with 13 CIEDs

Procedure time

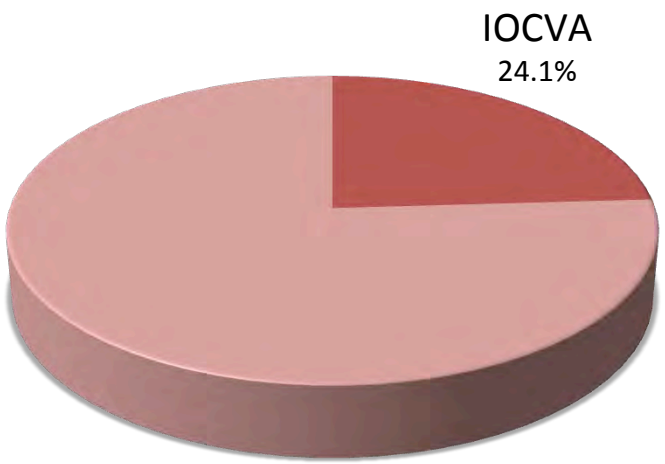

Total procedure time (average) 2.6 hrs
Time to establish IOCVA 32.8 ±11.1 min

Fluoroscopy time

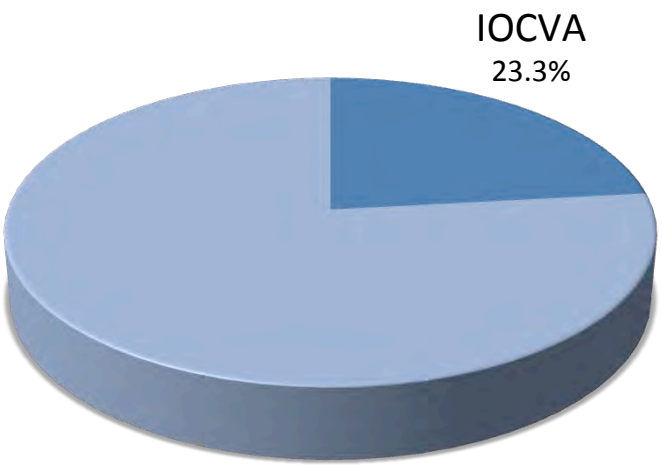

Total fluoro time (mean) 24.3 ±15.4 min
Fluoro time for IOCVA 5.6 ±3.8 min

Long-term performance of CIEDs (n=13)

- Cumulative experience: 7,546 days (20.7 patient-years)
- Mean duration of implant 2.5 yrs
- No lead or device failures to date
- One ICD removal at 830 days for bacteremia from infected femoral hemodialysis graft

Limitations of IOCVA

- Early experience, risks not fully explored
  - Proximity of SVC to pericardium, left pleura, aorta
  - Fragility of collaterals
- Improvised hardware… off-labeled use
  - Lacks of rigidity for controlled blunt dissection
  - Suboptimal directional orientation
  - Lack of control over exit angle
- Unknowns: removal, extraction

Cautions: Type 4 SVC occlusions

RA appendage overlies SVC in AP projection

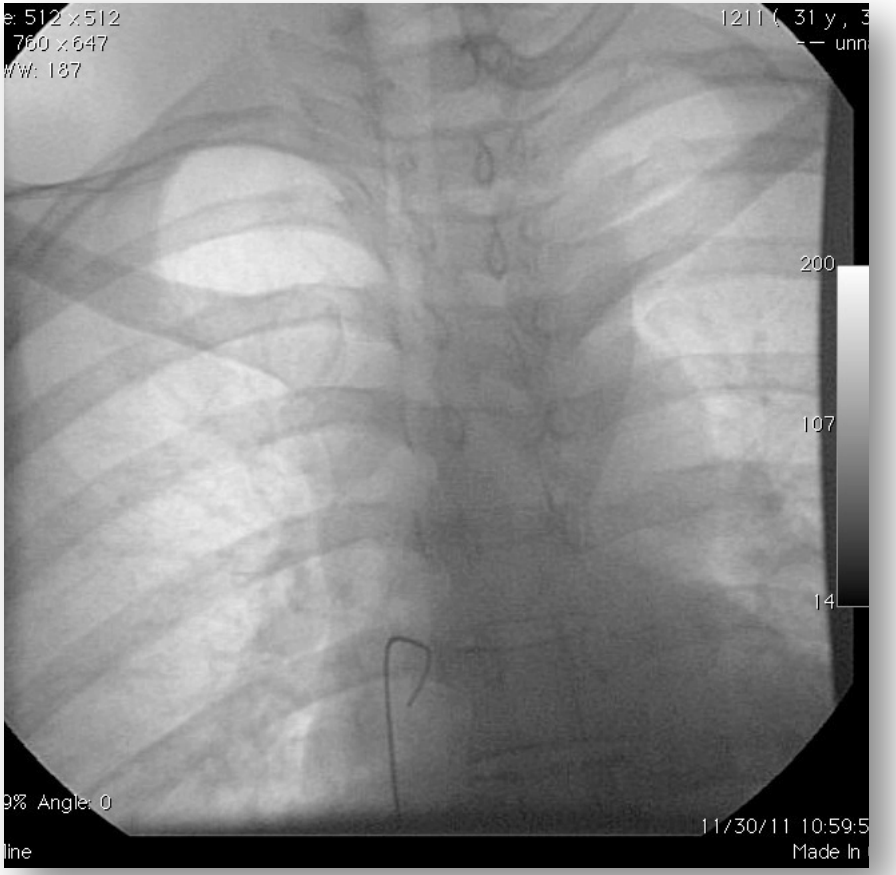

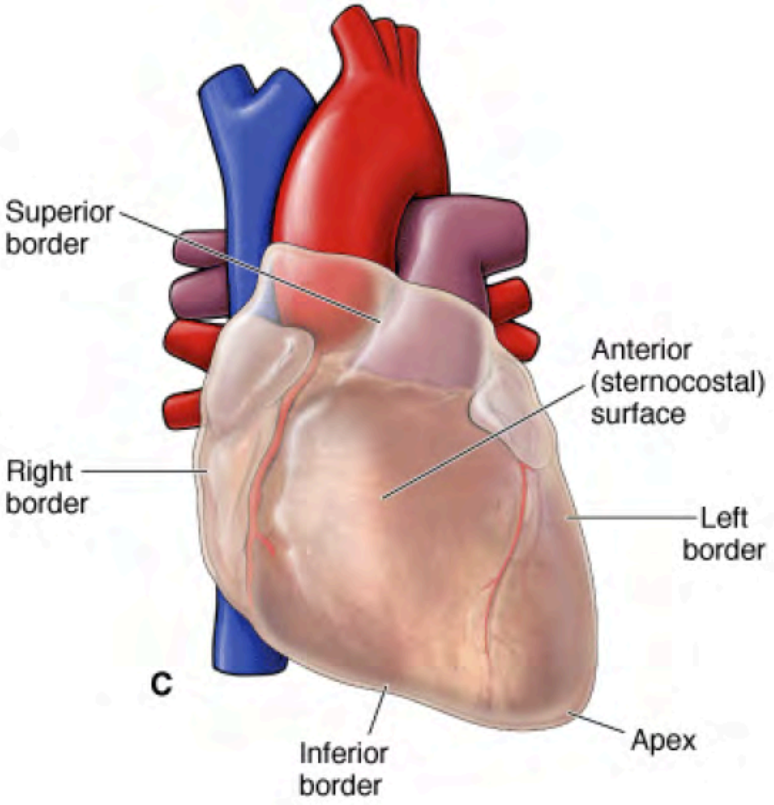

Precautions: Type 4 SVC occlusions

RAO 30º separates SVC stump from RAA

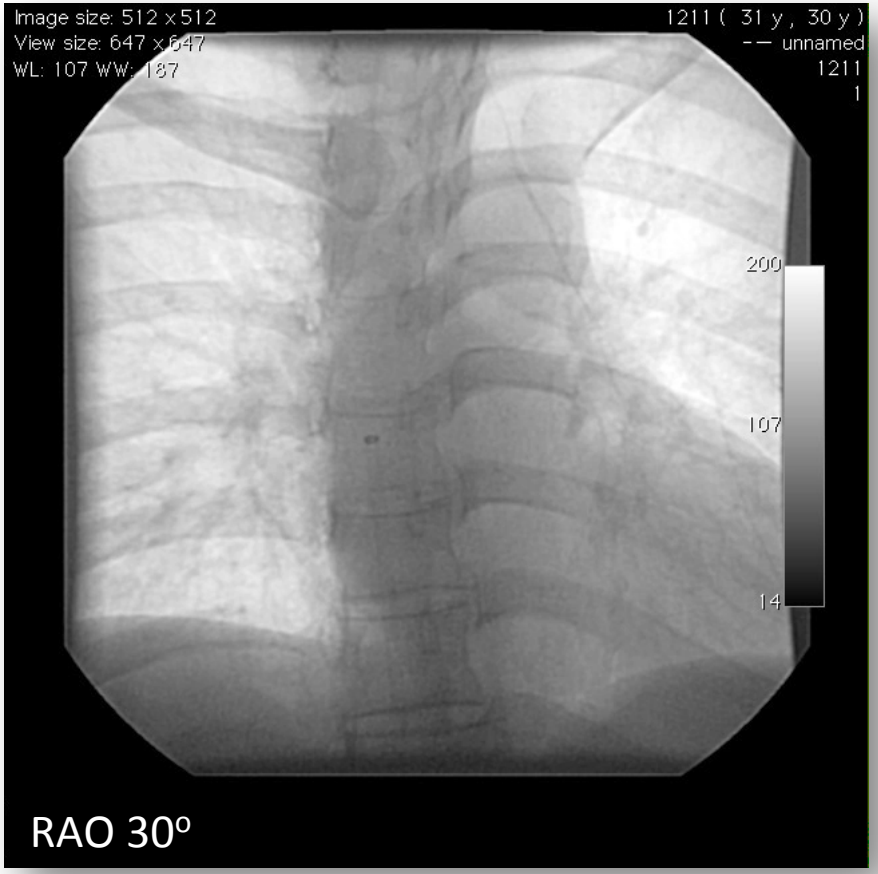

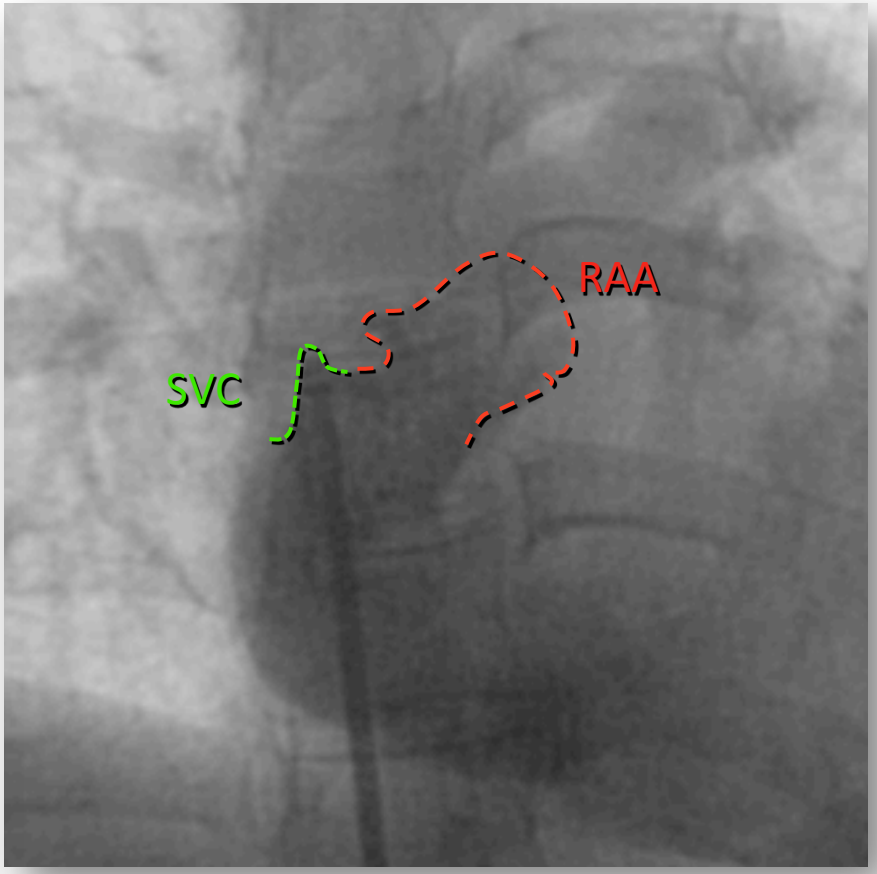

Exit angle issues

With long SVC occlusion, puncture may be parallel to skin

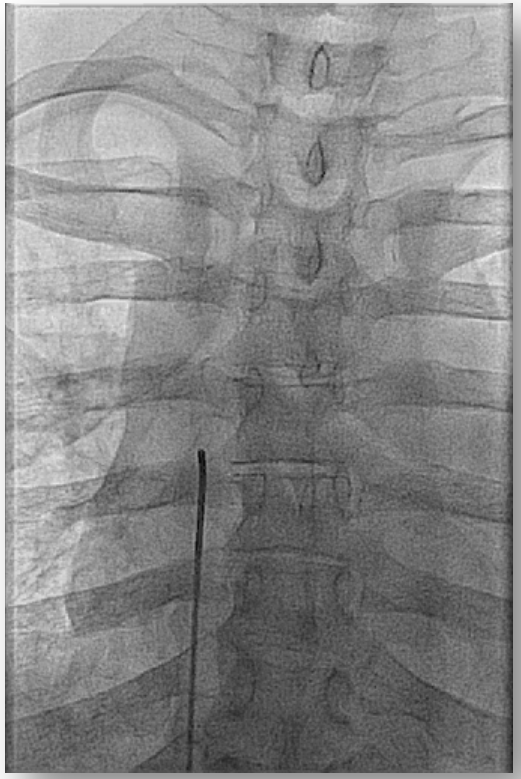

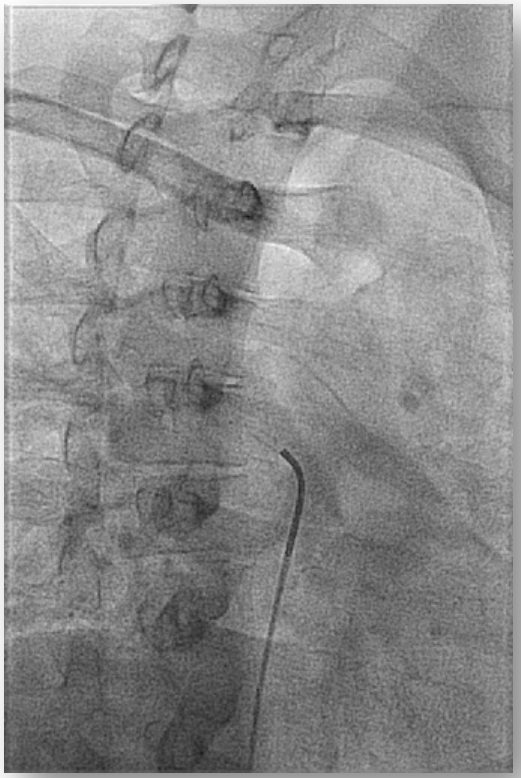

Navigating extra-anatomical spaces

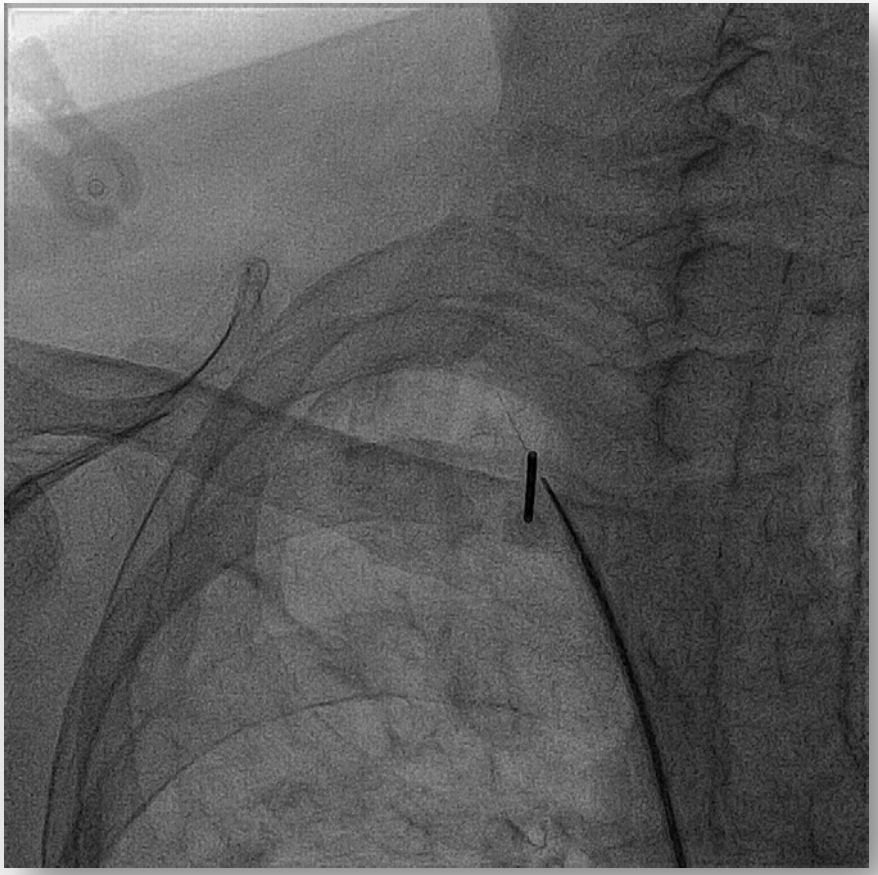

Next steps: dedicated hardware

Integrated system to provide blunt dissection and precise directional control of puncture

Interventional Device Implantation

Techniques for Overcoming Difficult Anatomy

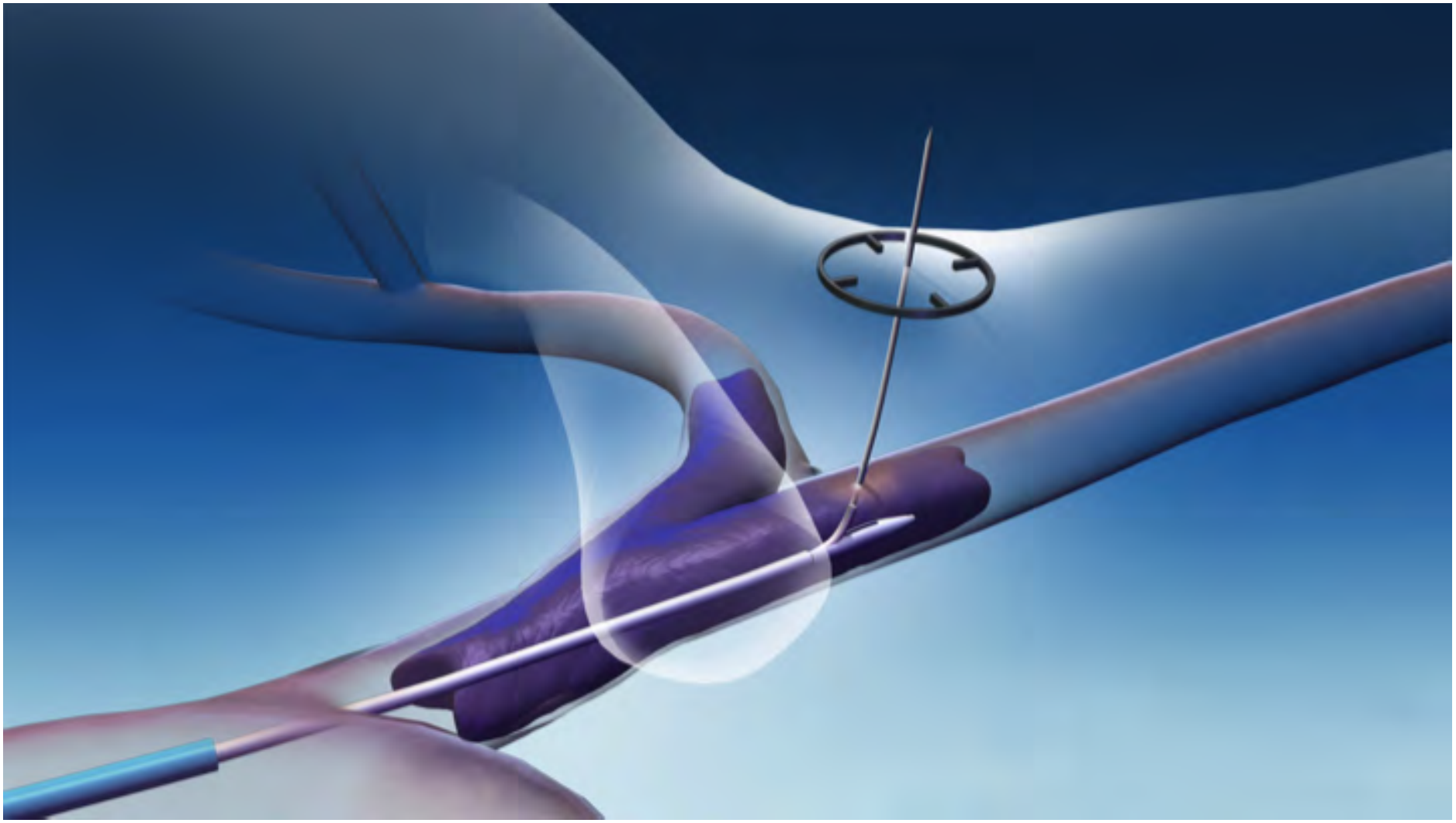

Interventional Device Implantation

Techniques for Overcoming Difficult Anatomy

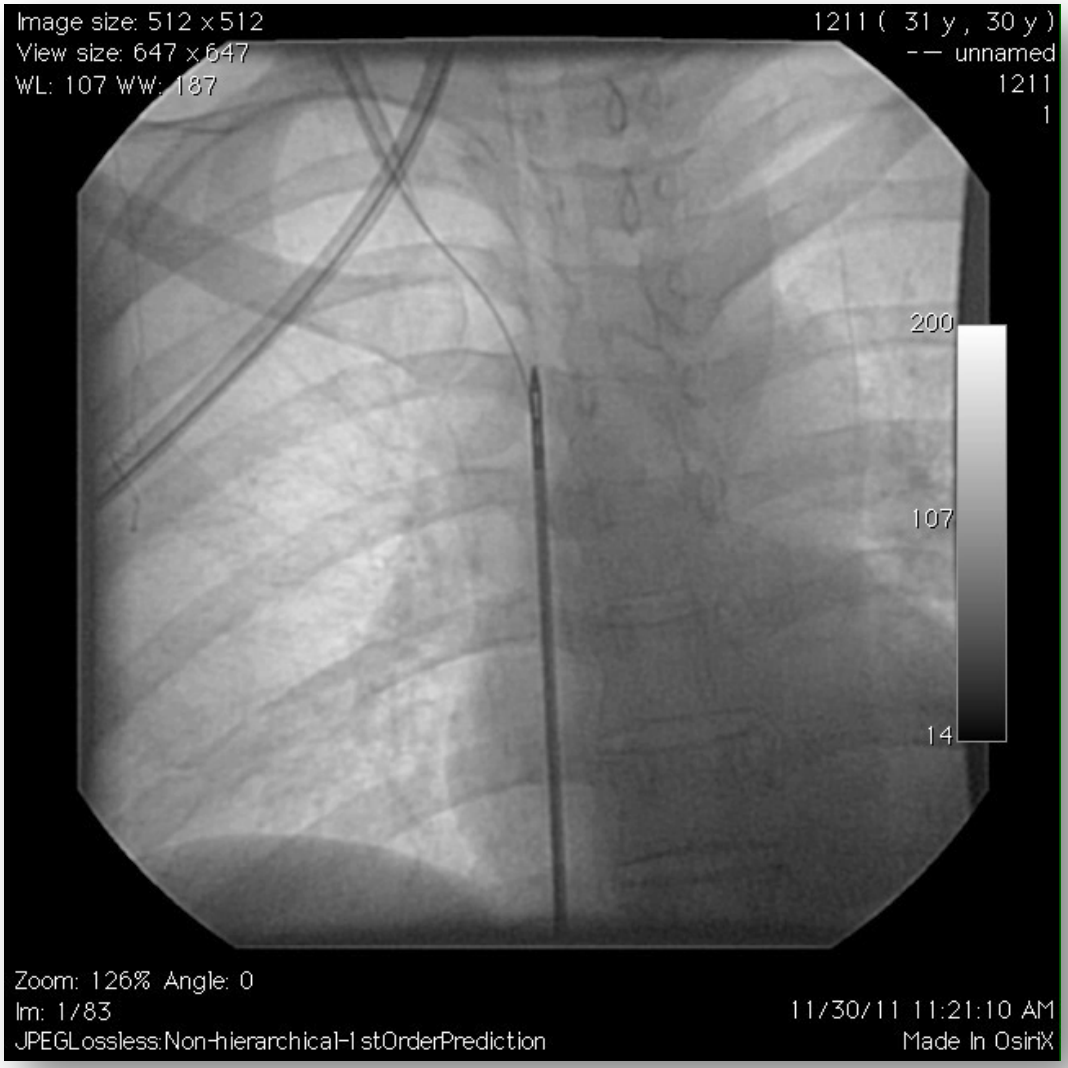

Time for a new paradigm

We must start recycling occluded veins

- Start with a long-term vein use strategy
- Consider future central vein requirements (dialysis, chemo, radiation, nutrition, etc.)
- Commit to preserving central veins
- Don’t use a new vein to add or replace leads
- Never use femoral veins for long-term devices
- Surgery as a failure mode

Thank you!